

# PAIN MANAGEMENT

A Practical Guide for Clinicians

SIXTH EDITION

Editor Richard S. Weiner



AMERICAN ACADEMY OF PAIN MANAGEMENT



**CRC PRESS**

---

Boca Raton London New York Washington, D.C.

The publishers, the authors, and the American Academy of Pain Management cannot assume responsibility for the validity of all materials contained in this book or for the consequences of their use. Some of the content represents an emerging area of study. As new information becomes available, changes in treatment and in the use of drugs may be necessary. The reader is advised to consult his or her healthcare practitioner before changing, adding, or eliminating any treatment. The reader is also advised to carefully consult the instruction and information material included in the package insert of each drug or therapeutic agent before administration. The publisher, authors, and the American Academy of Pain Management disclaim any liability, loss, injury, or damage incurred as a consequence, directly or indirectly, of the use and application of any of the contents of this volume.

**Library of Congress Cataloging-in-Publication Data**

Pain management : a practical guide for clinicians / executive editor, Richard S. Weiner.—6th ed.

p.; cm.

Includes bibliographical references and index.

ISBN 0-8493-0926-3 (alk. paper)

1. Pain—Treatment. 2. Analgesia. I. Weiner, Richard S., Ph.D.

[DNLM: 1. Pain—therapy. 2. Chronic Disease—therapy. 3. Disability Evaluation. 4.

Pain—diagnosis. 5. Patient Care Management. WL 704 P14656 2001]

RB127 .P33233 2001

6I6'.0472—dc21

2001037442

This book contains information obtained from authentic and highly regarded sources. Reprinted material is quoted with permission, and sources are indicated. A wide variety of references are listed. Reasonable efforts have been made to publish reliable data and information but the author and the publisher cannot assume responsibility for the validity of all materials or for the consequences of their use.

Neither this book nor any part may be reproduced or transmitted in any form or by any means, electronic or mechanical, including photocopying, microfilming, and recording, or by any information storage or retrieval system, without prior permission in writing from the publisher.

All rights reserved. Authorization to photocopy items for internal or personal use, or the personal or internal use of specific clients, may be granted by CRC Press LLC, provided that \$.50 per page photocopied is paid directly to Copyright Clearance Center, 222 Rosewood Drive, Danvers, MA 01923 USA. The fee code for users of the Transactional Reporting Service is ISBN 0-8493-0926-3/02/\$0.00+\$1.50. The fee is subject to change without notice. For organizations that have been granted a photocopy license by the CCC, a separate system of payment has been arranged.

The consent of CRC Press LLC does not extend to copying for general distribution, for promotion, for creating new works, or for resale. Specific permission must be obtained in writing from CRC Press LLC for such copying.

Direct all inquiries to CRC Press LLC, 2000 N.W. Corporate Blvd, Boca Raton, Florida 33431.

**Trademark Notice:** Product or corporate names may be trademarks or registered trademarks, and are used only for identification and explanation, without intent to infringe.

**Visit the CRC Press Web site at [www.crcpress.com](http://www.crcpress.com)**

© 2002 by CRC Press LLC

No claim to original U.S. Government works

International Standard Book Number 0-8493-0926-3

Library of Congress Card Number 2001037442

Printed in the United States of America 1 2 3 4 5 6 7 8 9 0

Printed on acid-free paper

---

# ETPS Neuropathic Acupuncture

---

*Bruce Hocking, D.Ac.*

## FOREWORD

The social and human costs of chronic pain are staggering. During the 20<sup>th</sup> century, chronic pain has disabled millions of people, costing hundreds of billions of dollars in rehabilitation costs and lost productivity in addition to untold human suffering (Statistics Canada, 1992). According to some statistics, 80% of these payments have been made for patients with neuromyofascial pain. For the future, there is little evidence to suggest that the rate of growth of chronic soft tissue pain conditions will decrease or even plateau.

Today, doctors and patients can choose from a variety of treatments, though surgery and prescription drugs are the most popular avenues in the United States. The major disadvantage associated with drugs or surgery is that they do not always solve the root problems; rather, they mask pain or surgically remove local pathology. Pharmaceuticals occasionally are effective, but can result in unpleasant interactions and side effects to a degree that reduces the quality of life for those who ingest them on a long-term basis. Moreover, the risks associated with drugs and surgery are not always outweighed by the benefits, as many patients actually feel worse.

A number of complementary and alternative modalities (CAMs) have been promoted as solutions to fill the void left by allopathic medicine. However, their relative efficaciousness may be regarded as sporadic. Progress in identifying a broader range of therapeutic benefits of CAMs has been hindered by considerable infighting among different disciplines, to a degree reminiscent of a quest to be the first to race up the hill, plant a flag, and claim victory in a winner-takes-all contest. While natural solutions do offer some relief in the battle

against chronic pain, long-term victory appears elusive when approaching a patient with a single modality or treatment philosophy.

The development of Electro-Therapeutic Point Stimulation (ETPS) therapy represents a turning point in the fight against chronic pain. Where surgery and prescription drugs fall short, ETPS provides nonsurgical, non-invasive treatment of chronic neuromyofascial pain. ETPS does not replace, nor does it dispute the validity of conventional medicinal approaches. Rather, ETPS recognizes that all therapeutic approaches must be examined to determine the most efficacious treatment for the patient. ETPS also recognizes that different therapies produce different responses and that the key to understanding the source of a patient's chronic pain is to perform an overall mechanical and neuropathic analysis of the body. This analysis helps to identify problematic areas that contort the body resulting in asymmetrical posture and motion; physical conditions that ETPS therapy believes can lead to degenerative changes and chronic pain throughout the body.

## INTRODUCTION

ETPS neuropathic therapy is a hybrid modality used in the treatment neuromyofascial pain. In its most basic form, ETPS therapy applies brief, staged, concentrated stimulation to points relating to different therapeutic systems. Patient assessments are performed at the end of each stage to determine therapeutic effectiveness. Through a series of systematic and reproducible protocols, the diagnosis and treatment of root causes of soft tissue pain can be completed with a high degree of accuracy.

The theoretical underpinnings of ETPS therapy are based on sound medicine, firmly grounded on the principles of acupuncture, osteopathic trigger points, neuromuscular and neural therapies. As such, the constituent elements of ETPS therapy are not new. Its unique contribution to pain relief however comes from the synthesis of different approaches, combining the therapeutic “pearls” of trigger, motor and acupuncture points with a mechanical analysis of the body. The result is a simple, easy-to-use series of protocols.

By following the recommended protocols, physicians are able to identify which stage(s) is/are most responsible for contributing to a patient’s pain condition. Stages deemed ineffective in producing positive therapeutic responses are eliminated from future treatments. Those stages producing positive responses are examined diagnostically to determine interrelationship(s) with the patient’s condition and are integrated into future protocols.

ETPS therapy does not isolate or treat a pain condition; rather, it is used to determine how the patient’s overall body mechanics and neuropathic/radiculopathic manifestations can be combined with acupuncture and trigger points to produce unique protocols. These protocols bridge many different treatment philosophies to provide therapeutic responses where other modalities fail to achieve successful results. Because it is effective in the diagnosis of root causes of pain, ETPS therapy can serve as an invaluable tool to all types of physicians in their efforts to substantiate current treatment and as an integrative tool for current protocols.

The therapeutic benefits of ETPS are based on four different physiological principles.

1. Circulation response. Increasing or decreasing circulation (called “chi” in Eastern therapies) can benefit the patient in a manner similar to the application of heat (vasodilation) and ice (vasoconstriction) in Western medicine.
2. Autonomic/parasympathetic response. A medium for chronic pain, the Autonomic Nervous System (ANS) covers over 90% of the body and consists of the sympathetic and parasympathetic nervous systems. ETPS stimulation of parasympathetic “gates” can have a calming effect on the body, providing the patient with immediate and long-lasting relief from pain, anxiety and insomnia.
3. Endorphin response. Endorphins are similar to morphine in their ability to reduce pain, but are thousands of times stronger and do not produce harmful side effects. Endorphins may be released through concentrated low frequency ETPS stimulation of neural points causing the pituitary to secrete endorphins thereby releasing adrenal cortico-atrophic

hormone (ACTH) and hydrocortisols for acceleration of soft tissue repair.

4. Myofascial release. Chronic pain is known to originate in neuropathy, or functional alterations of the peripheral nervous system (PNS). Neuropathy is always caused by muscle contraction, while radiculopathy is neuropathy at the spinal root. Relaxing contracted muscles relieves impingement of the nerves, reduces heightened sensitivity of pathways and improves patient’s ROM.

The balance of this chapter, divided into two main sections, provides an overview of ETPS therapy. Part A describes the six pillars of ETPS therapy, the core foundation of knowledge upon which the synthesis of different modalities is built. They are (1) acupuncture; (2) the relationship between radiculopathy, neuropathy and chronic pain; (3) the relationship between dermatomes and chronic pain; (4) the relationship between gait and chronic pain; (5) the relationship between scar therapy (neural) and chronic pain; and (6) ETPS stimulation. Based on this body of knowledge, Part B describes five ETPS protocols, all of which use an approach to treatment which allows therapists to diagnostically isolate and treat chronic pain concurrently.

ETPS therapy has proven successful in the treatment of various indications. These include back and neck pain, whiplash, TMJ, fibromyalgia, neuropathies, migraines, headaches, sport injuries, carpal tunnel, failed backs, post-operative radiculopathy, plantar fasciitis, frozen shoulder and shoulder pain, tennis elbow and most other neuro-myofascial pain syndromes. Due to the limitations of this forum, the description of ETPS therapy and related treatments will focus on back and neck pain, fibromyalgia and plantar fasciitis protocols.

## PART A: THE SIX PILLARS OF ETPS THERAPY

### ACUPUNCTURE

In order to utilize ETPS protocols effectively, therapists must have a basic, practical understanding of acupuncture. Long regarded as an effective modality for the treatment of pain, acupuncture contributes four key dimensions to the development of ETPS protocols: the release of endorphins, key acupuncture points, a numbering system for point location, and the movement of circulation and energy. Each dimension is discussed below.

#### The Release of Endorphins

Acupuncture has been scientifically proven to release endogenous morphines from the anterior pituitary (Andersson,

1999; Augustinsson, et. al., 1977; Cheng, McKibbin, Roy, & Pomeranz, 1980; Fisher, 1992; Martelele & Fiori, 1985; Pomeranz, 1981). Once released, internal morphines stimulate the release of ACTH and glucocorticoids, natural hormones that accelerate soft tissue healing. These powerful non-addictive opiates are circulated throughout the body to relieve pain and remain elevated for a period of 12 to 72 hours. All acupuncture points can release endorphins as long as a proper therapeutic response is achieved with needles or low-frequency stimulation. ETPS therapy activates endorphin response for overall pain relief through the application of low-frequency endorphin-releasing parameters to ETPS protocols (Christopher, Lorenzo, Zirbs, Chantraine, & Visher, 1992; Lehmann, Russell, Spratt, Liu, Fairchild, & Christensen, 1986; Pomeranz & Niziak, 1987)

### Key Acupuncture Points

Key acupuncture points are utilized for their beneficial therapeutic effects on the body. Distal points located on the extremities are stimulated to produce proximal pain relief and have been integrated into ETPS protocols to enhance pain relieving benefits. Four examples of distal points related to the treatment of back pain are described below.

- B 40 (Figure 54.1). An effective low back pain point integrated into circuits with ETPS back pain protocols to produce a highly effective therapeutic stage. Located on the midline of the transverse knee crease.
- K 3 (Figure 54.2). Is circulated with L4-L5 segmental levels for back pain that is worse in the morning. Located halfway between the apex of the medial malleolus and the Achilles tendon.
- B 60 (Figure 54.3). A powerful sciatic point circuted with L 4-L 5 segmental levels for afternoon back pain. Located halfway between the apex of the lateral malleolus and the Achilles tendon.
- Gb 34 (Figure 54.4). An influential point for muscles, tendons and tissues that should always be incorporated into the first stage of a standard protocol because of its ability to reduce muscular hypertonicity and spasticity throughout the entire body. Applying ETPS therapy to this acupuncture point is an absolute must for therapists who perform manual or soft tissue therapy on patients. Located inferior and posterior to the head of the fibula.

### Meridian Numbering System for Point Location

Soft tissue research suggests that there is a strong therapeutic connection between trigger, motor and acupuncture points and a low level of skin resistance (Gunn & Mil-

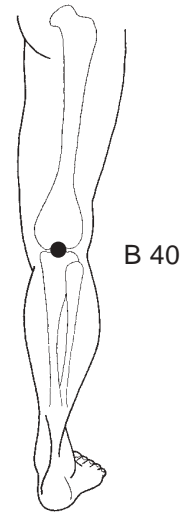


FIGURE 54.1 B 40 is a distal acupuncture point that influences proximal low-back pain

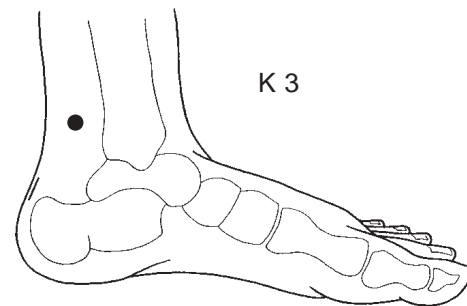


FIGURE 54.2 K 3 is a distal acupuncture point for low-back pain. Very effective for sciatica patients with pain aggravated in the morning

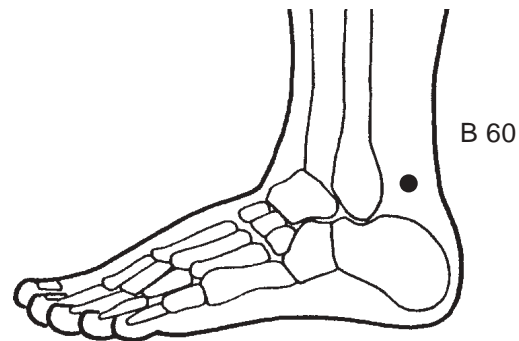
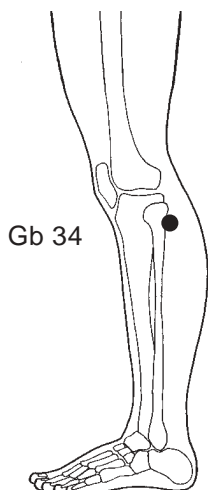


FIGURE 54.3 B 60 is a distal acupuncture point for low back pain. Effective for sciatica patients reporting aggravation in the evening

brandt, 1976; Hartley, 1989; Low & Reed, 1994; Robinson, Mackler & Snyder, 1995; Travell & Simons, 1992). For this reason, ETPS therapy uses the acupuncture meridian numbering system to assist in point location. In addition, the meridian system facilitates greater anatomic specificity when locating trigger points compared to palpation.



**FIGURE 54.4** GB 34 is the myofascial release point, also known as the “physical therapy point” in acupuncture. Applied in circuits for myofascial release of receptor muscles

To demonstrate the advantages of the meridian numbering system, consider acupuncture point Gb 21 and the upper trapezius trigger point. Although physically the same point, locating Gb 21 through the acupuncture meridian system is generally easier and will result in a more exact positioning compared to efforts to identify the upper trapezius trigger point through palpation alone.

### Circulation and Energy

Blood and circulation in ETPS therapy are assumed to be in line with the concept of *chi* in acupuncture. Chi is a difficult concept to translate into English, but can be described as flowing energy, vitality or life force. In the Oriental concept of medicine and the human body, the maintenance of health is achieved by releasing blocks, often caused by muscular tension, that restrict the flow of positive (yang) and negative (yin) energy. Many ailments, including neuromyofascial pain, are thought to be symptomatic of restricted or unbalanced chi.

Much of the skepticism with chi in Western culture largely centers on the inability of modern science to quantify this energy force. Rather than casting doubt on the existence of chi, the lack of recognition reflects the inflexibility and underlying hubris of modern Western paradigms. Acceptance of chi is not a prerequisite for practicing ETPS therapy; however, an open mind to its potential healing power is necessary.

ETPS adopts a simplified approach to chi. Positive or negative polarity (vasodilative or vasoconstrictive therapy) may be applied to trigger or acupuncture points depending on the historical response of the condition to heat and ice. Excessive or hyperfunctioning conditions usually respond better to vasoconstrictive therapy, while deficient or hypofunctioning conditions respond better to vasodilative therapy.

The circulatory setting is especially important with some chronic pain categories, such as fibromyalgia and reflex sympathetic dystrophy, where the traditional vasoconstrictive approach to pain therapy is poorly tolerated by patients. The therapeutic versatility necessary to treat positive and negative polarity is accomplished with ETPS’ neuro point stimulator, which has a current reversal function.

The importance of polarity in the treatment of pain should not be discounted. Based on our clinical experience there appears to be a 70:30 split in the chronic pain population: approximately 70% of patients respond better to vasoconstrictive therapy (sedation), while 30% report respond better to vasodilative therapy (tonification). With ETPS stimulation, therapists have the option of easily incorporating these ancient, but powerful healing philosophies into treatment protocols increasing flexibility and individualizing the therapy to better suit patient needs.

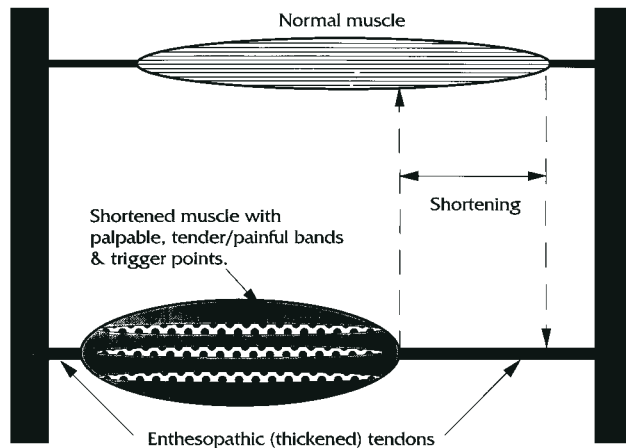
### THE RELATIONSHIP BETWEEN RADICULOPATHY, AND NEUROPATHY AND CHRONIC PAIN

#### Neuropathic Therapy

ETPS therapy has achieved significant success in relieving pain by integrating acupuncture philosophies into pain protocols. However, a singular reliance on acupuncture for treatment was found to be insufficient in addressing a number of neuropathic and mechanical issues. For instance, acupuncture offers no clear direction for the treatment of impinged nerves, nor does it integrate dermatomes and neuropathic pain patterns into protocols. Through years of experience, ETPS therapy has found that neuropathy plays a role in chronic pain and that its treatment through ETPS therapy can, in some cases, reduce or eliminate the need for drugs and surgery.

The introduction of neuropathic pain therapies into ETPS protocols greatly enhanced the understanding and therapeutic outcomes of chronic pain syndromes. The theories of radiculopathy and neuropathy suggest that nociception and inflammation are not the catalyst for chronic pain syndromes. Instead, the root of many chronic pain syndromes appears to be neuropathy and the muscular contractions causing neuropathy.

The cause of neuropathy is thought to be severe muscular contraction, that is, muscles that have contracted and remain contracted in the absence of action potential. Radiculopathy, defined as neuropathy at the nerve root, seems to have the strongest influence on chronic pain syndromes. Radiculopathy impinges nerves at the root and causing abnormal functioning of the pathways as well as the muscle tissue they innervate. In this way, radiculopathy creates an increased susceptibility to injuries along the dermatomes to the nerve endings.



**FIGURE 54.5** Top muscle illustrates muscular homeostasis. Lower muscle indicates muscle shortening, stretching of the tendons and straining of the joints.

ETPS electrical stimulation produces a myofascial release of contracted muscles. When muscles contract and remain contracted, there is an electrical depolarization within the muscle (Fambrough, Hartzell, Powell, Rash & Joseph, 1974; Becker & Gary Selden, 1987). ETPS direct current stimulus creates an electrical loop within the muscles, enabling electrical repolarization and thus, relaxation of the muscles (Figure 54.5).

### Radiculopathy and Chronic Pain

Poor postural lifestyle and repetitive strain motions, usually occurring while playing sports or in the workplace, contribute to a pooling of “micro” injuries in the paraspinal muscles. If a sufficient number of micro injuries build up over time, a relatively minor movement by the patient can initiate paraspinal muscular contraction severe enough to produce radiculopathy and chronic pain (Bradley, 1974; Gunn, 1980; Gunn, et al., 1976; Gunn, et al., 1978; Gunn & Milbrandt, 1976; Loh & Nathan, 1978; Sola, 1981; 1984, Thomas and Ochoa, 1993).

Radiculopathy caused by paraspinal muscular contraction is believed to affect the ANS by impinging nerves at the nerve root, usually proximal to the dorsal/ventral rami juncture. Nerve impingement reduces the flow of motor impulses throughout the nerve pathway. According to Cannon’s Law of Denervation (Cannon & Rosenbluth, 1949), a reduction of motor impulses through a nerve pathway produces disuse sensitivity and abnormal behavior within the receptor organ or tissue.

Radiculopathy influences tissue throughout the entire dermatome by reducing the flow of motor impulses at the nerve root. Nerve impingement and radiculopathy also influence distal pain by elevating acetylcholine (ACH) and adrenaline levels throughout the pathways (Cannon & Rosenbluth, 1949), thereby increasing susceptibility to extremity muscular contraction (i.e., neuropathy). The

environment created by increasing susceptibility to extremity neuropathy also increases susceptibility to distal injuries. Based on this series of relationships, it should be apparent that the treatment of most distal injuries must include an examination of the spine. In other words, if the spine significantly contributes to distal injuries, it should be a focus in pain therapy.

If paraspinal muscular contractions (radiculopathy) are a significant contributor to distal pain and/or disease, then the release of paraspinal muscles through ETPS therapy should provide relief to distal pain disorders. Therefore stimulating the paraspinal “Back Shu” points, which directly influence radiculopathic segments, can relax contracted muscles to a degree sufficient to reduce nerve impingement and allow the increase of motor impulses throughout the nerve pathways.

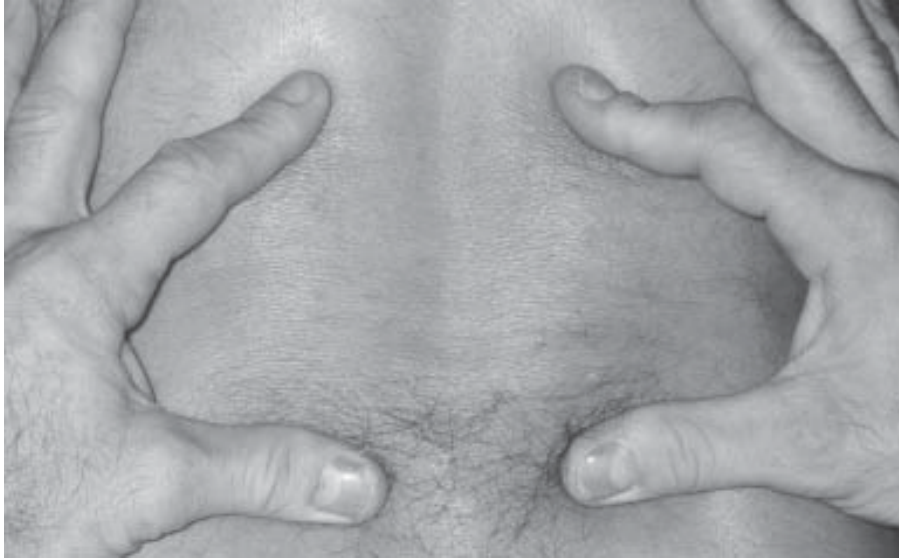### Manifestations of Radiculopathy and Neuropathy

Back Shu points are located paraspinally at the level of the spinous process interspace. Segmental levels with radiculopathy should be selected according to the following manifestations:

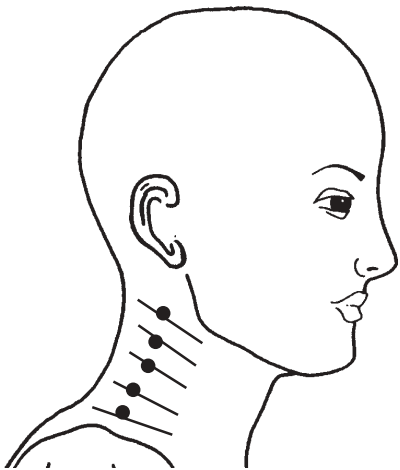
Bilateral signs of trophedema are usually located at segmental levels L1 – S3. Trophedema is a collagenic change in the skin that occurs when impinged nerves reduce the flow of motor impulses through pathways. Trophedema may be located with the “skin rolling” test, which will clearly identify the location in relation to non-trophic skin (Figure 54.6). Another manifestation, sudomotor, can be identified visually because it produces a general warmth and sweating in the vicinity of radiculopathy. Trophedema and sudomotor manifestations are commonly located in the lumbar sacral segmental levels of L1 - S3. Once the radiculopathic segments have been identified, they are correlated via dermatomes to distal injuries/pain conditions to determine root involvement in chronic pain conditions.

Motor bands may be palpated paraspinally throughout contracted muscles, usually T2–T12. Cross-fiber palpation will easily identify thick, ropy bands within paraspinal muscle bellies which often run the entire length of the muscle.

Posterior and lateral neck creasing at segmental levels, usually C2–T1 (Figure 54.7). Skin creasing suggests that some degenerative changes have occurred in the neck at the related segmental level. Occasionally, major creases will occur at every correlating segmental level on the neck.



**FIGURE 54.6** Illustration of trophedema (physical manifestation of nerve impingement, called radiculopathy) as demonstrated using the “skin rolling” test.



**FIGURE 54.7** Illustrates lateral creasing in the neck and the suggested location of myofascial release points throughout tight motor bands. DO NOT apply microcurrent stimulation anterior to the corner of the jaw (over the carotid sinus).

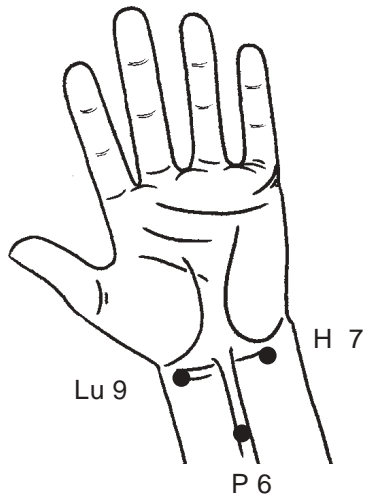
### Sympathetic Deregulation with Parasympathetic Points

The ANS is comprised of the sympathetic and parasympathetic nervous systems. Both neuropathy and radiculopathy stress the ANS by producing nerve impingement. Nerve impingement blocks the flow of motor impulses and deprive an organ or tissue of excitatory input (e.g., neural impulses) for a period of time causing disuse supersensitivity. Supersensitive nerve pathways and innervated structures react abnormally to stimuli, causing patients to perceive more pain than is actually being created (Brad-

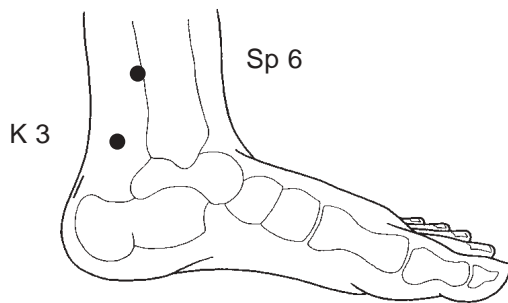
ley, 1974; Gunn, 1980; Gunn, et al., 1978; Gunn, et al., 1976; Gunn & Milbrandt, 1976; Loh & Nathan, 1978; Sola, 1981; 1984, Thomas and Ochoa, 1993).

Neuropathy, and radiculopathy in particular, increases the upregulation of the sympathetic nervous system by reducing the flow of motor impulses making treatment difficult due to the patient’s high sensitivity levels. Parasympathetic points treated with vasoconstrictive therapy deregulate the sympathetic nervous system, thereby permitting a more aggressive and proactive approach to patient treatment. Key parasympathetic points are as follows:

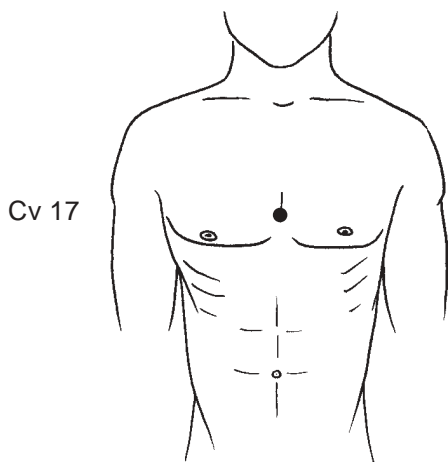
- Lu 9 (Figure 54.8). A powerful vascular/parasympathetic point. Located on the transverse wrist crease, in the a hollow on the ulnar side of the radius bone
- P 6. A good nausea and parasympathetic point. Located three fingers proximal from the most distal wrist crease, deep between the palmaris longus and flexor carpi tendons.
- H 7. A good mind calming and parasympathetic point. Located on the transverse wrist crease, in a hollow on the radial side of the thick, flexor carpi ulnaris tendon.
- Sp 6 (Figure 54.9). An immune, parasympathetic and distal pain point for perineum. Located four fingers superior to the medial malleolus and posterior to the tibia bone. Press against the posterior edge of the tibia bone to find this tender point properly.



**FIGURE 54.8** Three upper limb parasympathetic points Lu 9, P 6, and H 7, used to deregulate the Autonomic Nervous System (ANS), permitting continued therapy on supersensitive patients.



**FIGURE 54.9** Sp 6 and K 3 are lower limb parasympathetic points, for deregulation of lower viscera. Again, permitting continued therapy on sensitive patients.



**FIGURE 54.10** Acupuncture point for body calming. Also called “sea of tranquility”, Cv 17 should ONLY be treated on severe pain patients, and only AFTER all the above points have been treated.

- K 3. A low back pain, congenital energy and parasympathetic point. Located in the hollow midway between the medial malleolus and the Achilles tendon. Used for morning back pain, circuted with B 25 (L4-L5 interspace).
- Cv 17 (Figure 54.10). A respiratory and parasympathetic point. Located on the midline of the sternum, horizontal with the fourth intercostal space.

### THE RELATIONSHIP BETWEEN DERMATOMES AND CHRONIC PAIN

The application of ETPS therapy requires an inspection of dermatomes for their interrelationship with segmental levels. This important inspection will provide evidence in determining if radiculopathy is contributing to a pain condition. Distal injuries are correlated first with their dermatomes and second proximally to the segmental levels that innervate the dermatomes. ETPS stimulation to paraspinal points that influence the dermatomes and nerve pathways will relax contracted muscles, allowing for increased motor impulses throughout pathways, improved nerve regeneration and reduced pain levels (Figure 54.11).

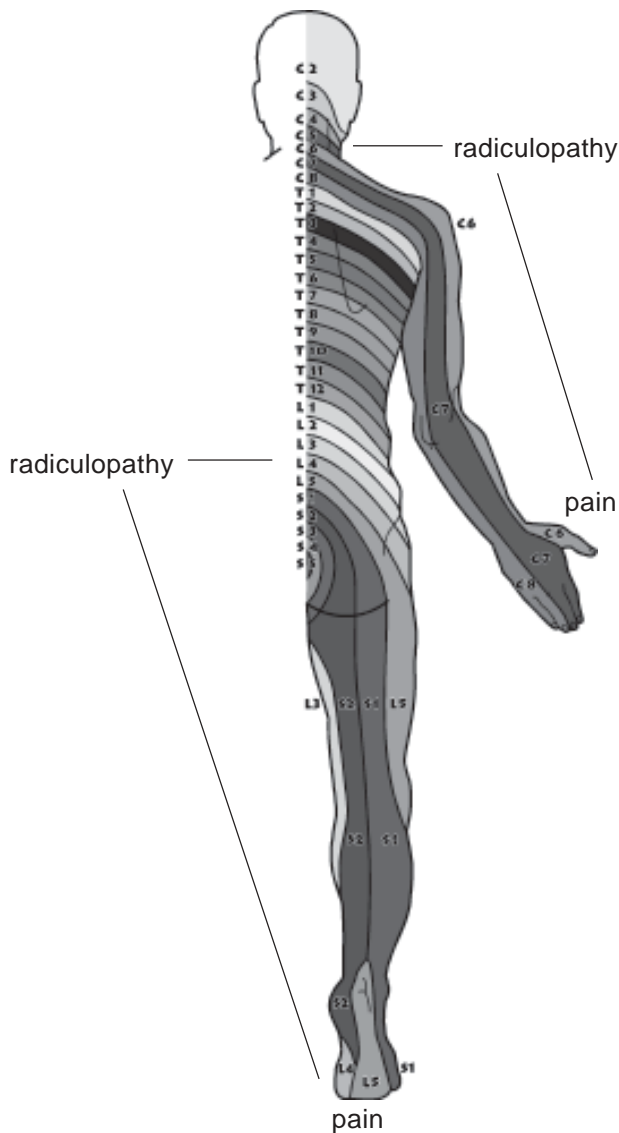
There are three ways to integrate the nerve root with pathways and dermatomes: segmental nerve root and paraspinal stimulation, nerve pathway treatment, and integrative circuits and nerve ending treatment using distal dermatome and acupuncture points.

### Paraspinal Point Location

Radiculopathy and nerve impingements often occur paraspinally at the segmental nerve root and innervate the injury or pain area. Locating and treating paraspinal points corresponding to radiculopathic segmental levels is an important step in the application of ETPS protocols.

These paraspinal points are located approximately 1 in. bilateral to the midline on the medial border of the erector spinal muscles ridge. When stimulated, they provide a relaxing effect on the deep paraspinal muscles of semispinalis, longissimus and iliocostalis, all of which influence the entire spinal column and the extremities through the dermatomes. One of the most successful applications of this ETPS paraspinal therapy is at the L4-S2 segmental levels, which innervate the lower limbs and feet. Paraspinal stimulation of L4-S2 segmental levels can provide significant pain relief to the vast majority of patients suffering from lower extremity pain such as plantar fasciitis, peripheral neuropathy, metatarsalgia and heel spurs.

The integration of paraspinal segmental points into the clinical pain setting is an effective therapy. Pain must travel through the pathways and all pathways are connected to the spinal cord. Spinal Back Shu points are selected according to neuropathic manifestations



**FIGURE 54.11** Illustrates nerve root impingement called radiculopathy, influences distal pain throughout the extremities.

observed at the segmental levels that innervate the injury or pain syndrome. Different manifestations will affect different segmental levels. Brief stimulation of these spinal points with ETPS therapy provides an easily integrated, diagnostic and effective approach to chronic pain management.

### Integrative Neural Circuits

Circuits have been used in acupuncture therapy for centuries. A circuit consists of a series of stimulated points integrated into a single treatment to produce enhanced therapeutic benefits. In ETPS therapy, selected acupuncture, trigger and motor points are circuited for their ability to isolate nerve pathways and relax specific muscles and groups of muscles. Segmental level L2-L3 has, for instance, a strong analgesic relationship with the lumbar

region. In traditional acupuncture, this segmental level relates to the kidneys, widely regarded as powerful organs in pain therapy, which indirectly influence the spinal column. Paraspinal points at segmental level L2-L3 (B 23 in acupuncture) are circuited with B 40 (a distal acupuncture point for the lower back) to produce a powerful analgesic response for lower back pain.

Another circuit combines segmental levels L4-L5 (B 25 in acupuncture) with the important low back pain point B 60 (lateral malleolus). B 60 strongly influences the L5 dermatome, and produces a strong analgesic response in sciatic patients when circuited with the L4-L5 nerve roots. This circuit is ideal for patients whose pain gets progressively worse throughout the day.

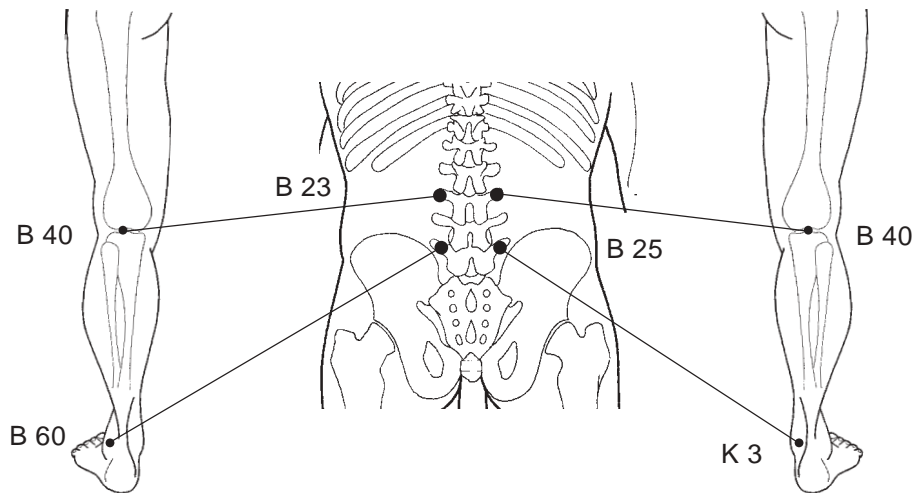
The circuit L4-L5 (B 25) and K 3 (medial malleolus, opposite B 60) provides another opportunity to individualize pain treatment to meet patients' needs. This circuit is ideal when sciatic/low back patients display morning pain and stiffness that may or may not improve throughout the day. Recognizing that patients with morning back pain and stiffness often display weak kidneys, circuited B 25 and K 3 treats the kidneys by helping to relieve stiffness and stimulate nerve roots, thereby addressing radiculopathic and energetic contributions to injury. (See Figure 54.12.)

In ETPS therapy, there are numerous circuits that produce outstanding responses. A therapist who possesses a working knowledge of dermatomal patterns and extremity acupuncture points may use this understanding to create integrative circuits. Circuits are created between the dermatomal nerve root (spinal points) and any major trigger/acupuncture points located distal to the injury. These circuits permit therapists to release individual or groups of muscles in one application, ultimately saving manual therapists time and effort.

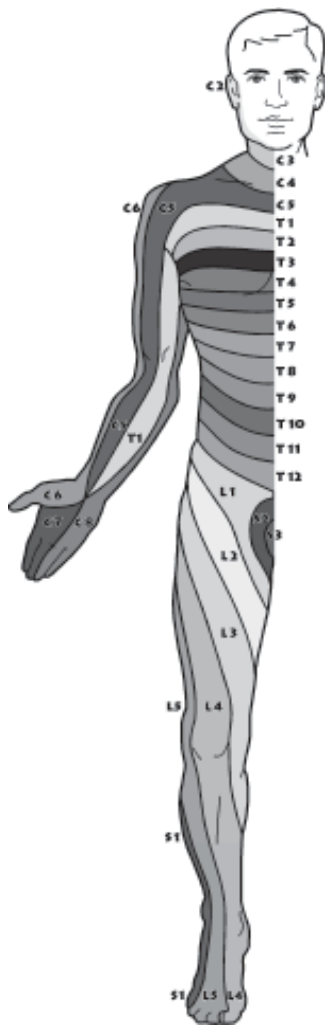
### Integrating Dermatome Points

The final approach to integrating segmental/dermal therapy is the treatment of dermatome points located on the lateral and medial side of the nail base at the tips of the fingers and toes. All dermatomes and meridians connect the extremities with the midline. Therefore, if stimulation is applied at the nerve root to alleviate distal pain, stimulation may also be applied to the extremities to alleviate proximal pain. Stimulation is applied to dermal points on the fingers and toes relating to pain along dermatomes and meridians. In our experience dermatome point stimulation has been found to be a successful treatment for a significant percentage of patients who are unresponsive to nerve root and pathway treatments and an integrative adjunct to improve outcomes. (See Figure 54.13.)

Successful applications of this circuit are often applied on the feet. Segmental levels L4-S2 innervate the feet



**FIGURE 54.12** Illustrates neural circuits performed in ETPS therapy. Circuits B 23-B 40 are treated bilaterally to reduce upper leg pain and calm nerve pathways resulting from radiculopathy. Circuits B 25 – K 3 are integrated bilaterally for back patients with pain aggravation in the morning. Circuits B 25 –B 60 are integrated bilaterally for back patients with pain aggravation in the afternoon or evening.



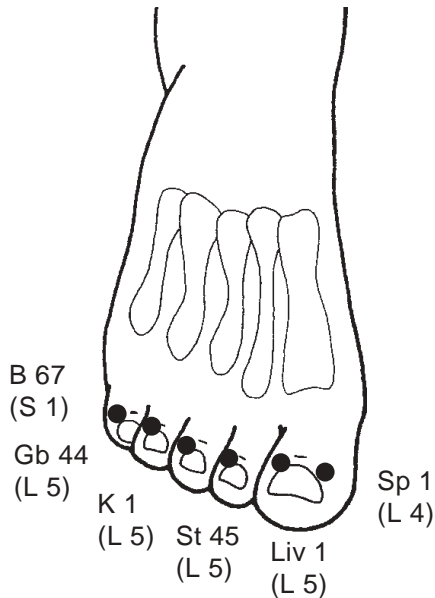
**FIGURE 54.13** Illustration of the segmental dermatomes.

with the fourth and fifth toes representing the L5 and S1 dermatomes. These two points may be stimulated with

ETPS individually to produce an effective analgesic response in the lower back. More importantly, these dermal points also represent the end of the two acupuncture meridians, the gall bladder and the bladder, both of which have a strong influence over hip and back pain. Gb 44 is located on the fourth toe and B 67 is located on the fifth “baby” toe. Proximally following the meridians, the gall-bladder meridian influences the lateral leg and hip region, while the bladder meridian influences the spine. Therefore, these two points may be used to diagnostically determine root causes of low back or hip pain. If Gb 44 is more sensitive than B 67, the piriformis-iliotibial fascial muscles (and therefore the gait) are more likely to be responsible for a patient’s back pain. If B 67 is more sensitive, local spinal pathology, such as a bulging disc, is most likely responsible. Through years of ETPS experience, the sensitivity of these two points has proven to be an accurate diagnostic indicator of pain, mechanical imbalances or neuropathy along the meridian or the muscles that intersect the meridian. (See Figure 54.14.)

### Myofascial Release with Dermatome Therapy Points

The cross integration of dermatomal points with acupuncture meridians displays the flexibility of ETPS therapy. Dermatome points correspond strongly with jing well points, acupuncture points used to treat acute diseases in related organs. Dermatome point stimulation is also an effective treatment for myofascial release of muscles relating to, or intersecting with, correlating meridians. The integration of dermatomal and jing well points has proven successful in the treatment of hard to reach muscles, such as the psoas, and difficult injuries, such as adductor groin. Far from experimental, this technique has been applied for decades in many therapies, including Electro Acupuncture According to Voll (EAV) therapy, with much reported success. The example described below, focusing on the



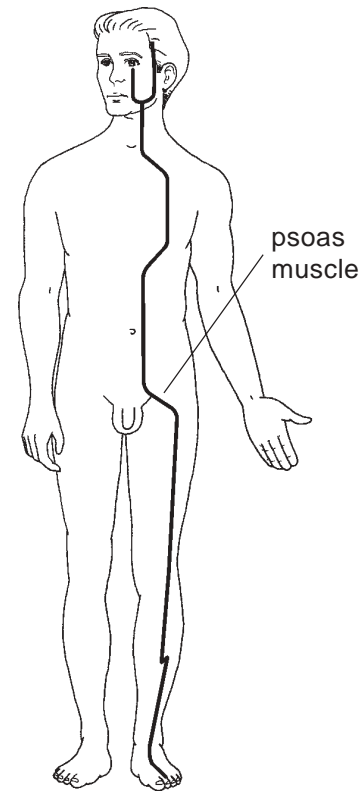
**FIGURE 54.14** Distal acupuncture points which correspond to the segmental dermatomes. Located at the base of the nail, on the illustrated side.

stomach meridian and the psoas muscle, demonstrates an effective application of this approach.

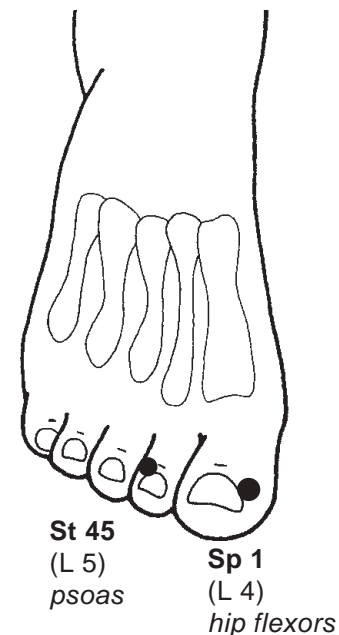
There is a strong myofascial/therapeutic relationship between the psoas muscle, the stomach meridian and the corresponding jing well point. If the stomach meridian is followed proximally from the distal end at St 45 (located on the lateral base of the second toenail), the meridian travels through the quadriceps and intersects the psoas muscle (Figures 54.15 and 54.16). Stimulation of St 45 provides effective myofascial release of the corresponding ipsilateral psoas muscle. Widespread success of this technique has been witnessed at ETPS workshops and reported through clinical feedback, with approximately 80% myofascial release occurring within minutes of treatment. This unique ETPS response can save manual therapists a significant number of hours of therapeutic work in addition to rescuing patients from the agony of deep manual therapy.

Another therapeutic pearl is the stimulation of Sp 1 (L4 dermatome point located at the medial nail base of the first toe) for groin pain. Traditionally used for acute menstrual cramping, this technique has proven successful in relieving pain associated with difficult to treat adductor groin injuries in ETPS therapy. In many cases, successful results have been achieved within minutes of treatment.

The integration of dermatome points provides one of the simplest approaches to the treatment of pain. With a working knowledge of dermatomal patterns and acupuncture meridians, a therapist can quickly treat any proximal segment or muscle with the related dermal points.



**FIGURE 54.15** Illustrates the stomach meridian and the anatomical location of the psoas muscle.



**FIGURE 54.16** Illustrates the integration of acupuncture “jing well” points with meridians for myofascial release of psoas and hip flexor muscles.

## THE RELATIONSHIP BETWEEN THE GAIT AND CHRONIC PAIN

For many years, different fields of science and meridian research have studied the mechanics of the human body in order to identify potential relationships with chronic pain. Based on our experience with ETPS therapy, there appears to be a causal relationship between the gait and several chronic pain syndromes. In more precise terms, body asymmetry produces an irregular gait that stresses the ANS, which in turn causes pain (Figure 54.17).

“Gait” refers to the postural positioning of the iliac crest and its subsequent relationship to the spine and lower limbs. A positive right ‘gait’ will, for instance, produce a shortened right leg and a length discrepancy between the two legs. Leg length discrepancy (LLD) leads to asymmetrical movement with a disproportional amount of body weight shifted to the longer and often weaker leg (Figures 54.18 and 54.19).

Positive gait irregularities also stress the spine to produce misalignment of the segments, asymmetrical movement and paraspinal degenerative changes. These mechanical imbalances precipitate muscular contractions and radiculopathy (Friberg, 1983; Yochum & Berry, 1994). Radiculopathy leads to denervation supersensitivity of

the nerves and an upregulation of the sympathetic nervous system. Thus, radiculopathy not only contributes to and perpetuates chronic pain, but can also serve as the major precipitator of chronic pain syndromes in many cases.

After studying hip positioning and mechanical relationships to the gait, there appears to be a neuropathic, and therefore, myofascial component to asymmetrical positioning. If contracted, the piriformis muscle, and its specific attachments, may be responsible for gait misalignments. Viewed through the ETPS framework of analysis, the trochanter will be pulled upward (superiorly) in the acetabulum if the piriformis contracts, thereby producing a positive, or higher, hip on one side. This imbalance in turn pulls up the femur to create a LLD. Therefore, the first step in treating gait imbalances should be a manual correction of the gait and LLD after a visual inspection has been completed.

Current therapeutic solutions to LLD include lifts and orthotics. The problem with these solutions is that they do not specifically address the root causes of LLD. The dominant one-sided nature of human body, combined with the prevalence of repetitive-action lifestyles, places stress on the piriformis muscle resulting in contraction. If true, leg length corrections that do not address the gait may actually contribute to poor body mechanics and a continued stressing of the ANS.

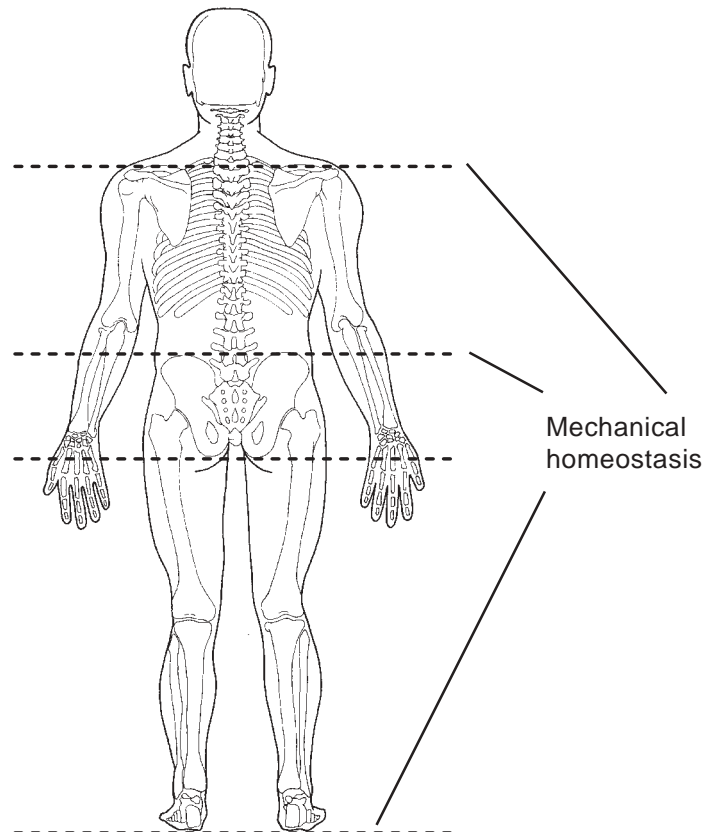
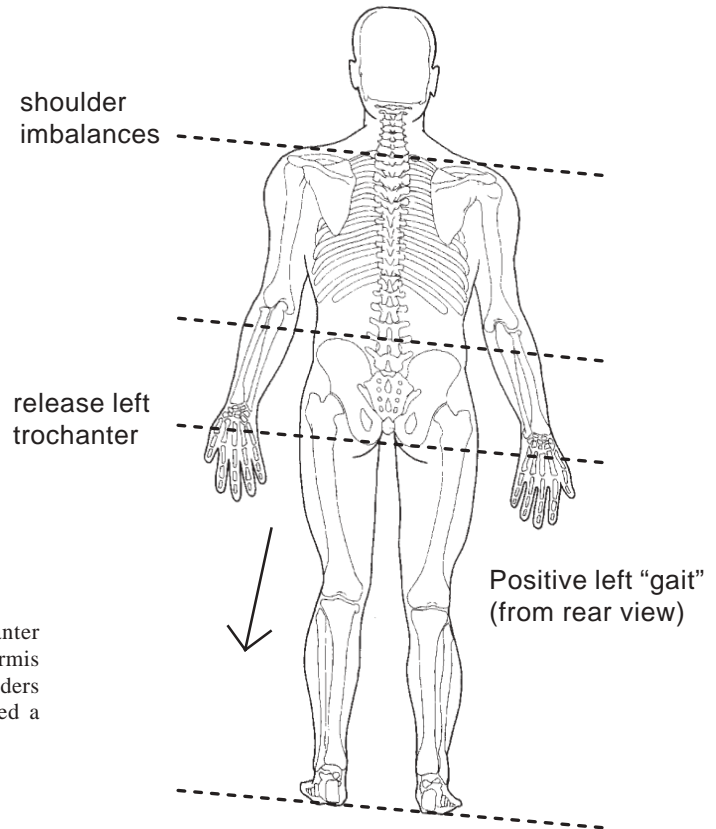
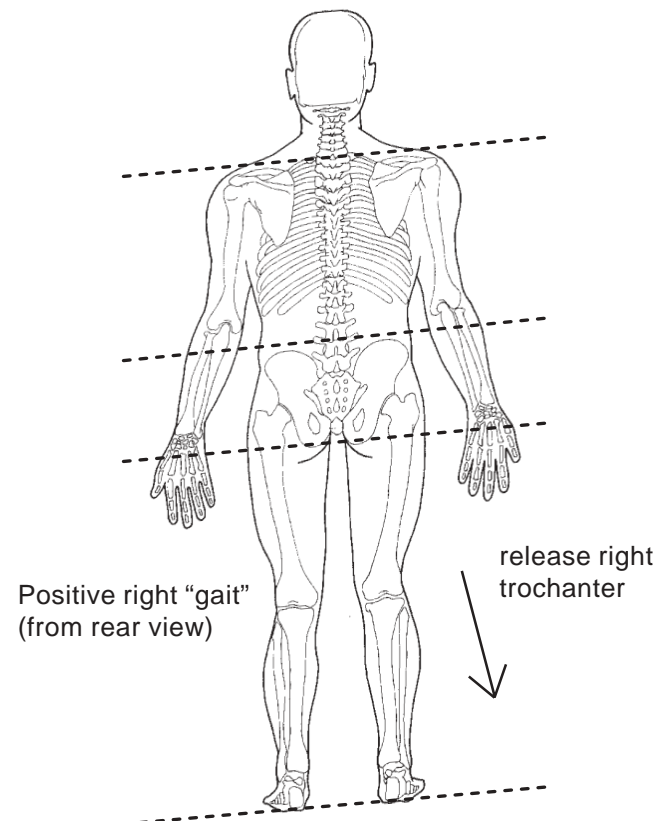


FIGURE 54.17 Mechanical homeostasis, as seen by level hip, shoulders and trochanters.



**FIGURE 54.18** Illustrates superior movement of left trochanter in the acetabulum. This is often due to contraction of the piriformis muscle, which precipitates mechanical imbalances of the shoulders and hips, and leg length discrepancy of the left leg. Called a positive “left” gait.



**FIGURE 54.19** Illustrates superior movement of right trochanter in the acetabulum. This is often due to contraction of the piriformis muscle, which precipitates mechanical imbalances of the shoulders and hips, and leg length discrepancy of the right leg. Called a positive “right” gait.

### Manual Piriformis Stretch

In ETPS therapy, a specific manual therapy called a piriformis stretch is performed in order to reposition properly the trochanter in the acetabulum. In other words, realign the hip and pelvis. Stretching the piriformis until the trochanter and acetabulum restore proper gait balance will produce symmetrical leg lengths and mechanical homeostasis throughout the body. With the patient in the prone position, approach from the right (R) side, place your R hand on the superior angle of the trochanter at a 45° angle. Lift the leg 6 in. above the knee with the left (L) hand and abduct the leg to a 30° angle or until trochanter becomes prominent on the R hand.

In one motion, rotate your R hand medially and use the L hand to gently lift the R leg on midline (beside the L leg). If properly executed, this piriformis stretch places the trochanter in the proper anatomical location creating hip, spine and mechanical symmetry throughout the body. In some cases, the shortened leg is so badly displaced in the trochanter that this realignment technique will make the shorter leg longer than the other one. For this reason, the piriformis stretch should always be performed bilaterally to ensure symmetry of the hip and pelvis. The importance of symmetry throughout the hip and pelvis region in general, and the piriformis stretch in particular, cannot be understated in the fight against chronic pain.

### Myofascial Release of Piriformis using Circuits

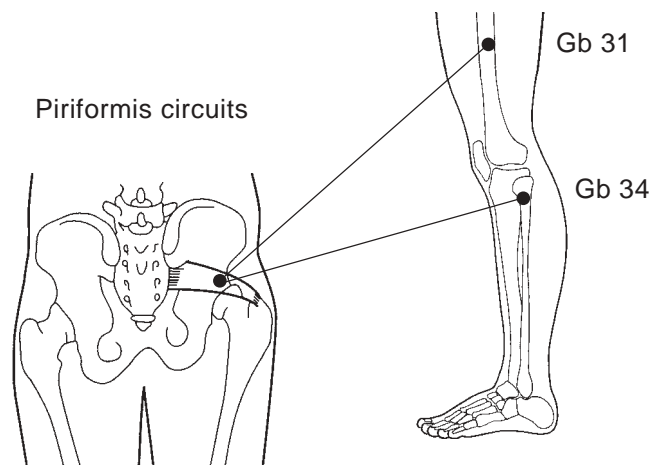
After achieving mechanical repositioning, a myofascial release on the piriformis must be completed to prevent the leg from recontracting and producing the same positive gait and LLD. Without this release, a repetitive lifestyle would constantly pressure the piriformis to recontract,

thereby misaligning the gait and creating the conditions for the cycle to reappear.

Two circuits will release the piriformis, hip and lateral thigh muscles (Figure 54.20). The first is the piriformis-IT circuit. To start, palpate cross-fiber at the superior angle of the piriformis muscle. Thick motor bands are often easily palpated where piriformis glute min/medius meet. Apply one circuit to the most tender trigger point found within the motor bands; the other circuit should be applied to the trigger point of the ili-otibial band (found at the end of main rae with hands at the side (Gb 31 in acupuncture). Simultaneous stimulation of these two points often provides a strong myofascial response between the hip and lateral thigh muscles, creating immediate pain relief. It also allows the piriformis muscle to relax and facilitates proper positioning of the trochanter in the acetabulum.

Piriformis-Gb 34 is the second circuit. For this treatment, keep one modality on the same tender piriformis trigger point as above. The other modality is placed on Gb 34, the acupuncture point responsible for relaxing muscle tissue (inferior and posterior to the head of the fibula). This circuit performs an overall myofascial release and often relaxes muscular tissue not released in the first circuit.

To perform a myofascial release, two circuits must be created. The first is a circuit between the superior angle of the piriformis trigger point and the middle of the IT band (acupuncture point Gb 31). The second circuit is performed between the superior angle of the piriformis trigger point and the myofascial acupuncture point Gb 34 (inferior/posterior to head of fibula). These two circuits, performed bilaterally, are effective in maintaining a myofascial release of the piriformis and related gluteal and hip muscles responsible for gait misalignment.



**FIGURE 54.20** Piriformis circuits are performed to produce myofascial release of hip and leg muscles responsible for gait imbalances. They are applied bilaterally after mechanical realignment for optimal, lasting results.

The integration of a piriformis stretch/release is an important part of ETPS protocols. Its introduction can significantly improve soft tissue and mechanically-based therapeutic outcomes of any pain program. Once learned, the stretch can be applied in seconds and should be integrated into any pain management protocol.

### THE RELATIONSHIP BETWEEN SCAR THERAPY AND CHRONIC PAIN

Occasionally, patients may continue to suffer from pain after receiving treatment based on the above-mentioned therapeutic steps addressing the mechanical and myofascial components of chronic pain. Therefore, other sources of pain, such as neural therapy, have been included into ETPS protocols to treat scars throughout the dermatomes and meridians.

Neural therapy, the stimulation of scars for pain reduction and homeostasis, has been an accepted and proven form of neuromyofascial pain therapy for years. Neural therapy theory suggests that scarring restricts the flow of energy, disrupts the lymphatic and circulatory systems and interferes with muscle energy and mechanical stability of the body. All of these systems are adversely affected when a scar influences the dermatome or meridian to which it is connected.

For unresponsive pain conditions, inspection for distal scarring along the dermatomes or distal/proximal scarring along the meridian can be helpful in determining where to treat the pain condition next. If a scar is located in the corresponding dermatome or meridian, ETPS stimulation along the scar perimeter can provide immense relief to suffering patients. This approach is especially effective if there is extremity joint scarring, especially around the ankle and knees.

Based on current medical knowledge, it is not clear why scar stimulation is an effective form of treatment for some patients. One leading theory suggests that neural therapy “breaks up” the collagenic tissue surrounding the scar. Intermittent stimulation of the scar perimeter, sometimes called “surrounding the dragon,” is thought to break up scars, thereby permitting an increase in the functioning and homeostasis of the lymphatic, energetic, neural and circulatory systems. Irrespective of the pathology, scar treatment has been found to reduce local pain. The stimulation of scars relative to the injury via dermatomes and meridians has produced impressive therapeutic responses with some hard-to-treat chronic local pain as well as discomfort along the dermatome and meridians

### APPLICATION OF ETPS STIMULATION

Traditional stimulation of trigger, motor and acupuncture points includes invasive techniques such as acupuncture and hypodermic needles and non-invasive modalities such as TENS and microcurrent stimulation. Both TENS and

microcurrent stimulation may be applied with traditional pads or via point stimulation. Truly integrative therapies, such as ETPS, employ potent, versatile and patient-friendly stimulation. Based on these criteria, an initial treatment utilizing invasive needles is relatively less productive because it damages tissue and requires a recovery and/or an incubation period of 20-30 minutes to determine therapeutic efficacy. In contrast, ETPS therapy can often generate positive results in a matter of minutes.

ETPS therapy is best applied with noninvasive direct current (DC) stimulation. Alternating current (AC) is ineffective because it does not produce the square wave necessary for the stimulation of an endorphin response (Christopher, et al., 1992; Lehman, et al., 1986; Pomeranz et al., 1988; Pomeranz & Niziak, 1987). Furthermore, AC cannot by definition produce a monophasic pulse, a form of stimulation that can be reversed in order to produce the highly sought after vasodilative and vasoconstrictive responses (Bronzino, 1998). DC is also favored for its ability to repolarize contracted muscle tissue, a necessary physiological response for the release of myofascial tension. Finally, DC stimulation is preferred because it produces few, if any, adverse side effects. With no significant iatrogenic responses, noninvasive and concentrated DC stimulation can be used to treat multiple systems at one sitting, thereby creating an opportunity to outperform traditional needle therapies that concentrate on one system in each treatment. The result is greater therapeutic versatility and productivity.

ETPS applies DC microstimulation in stages to determine the root cause of chronic pain syndromes. Concentrated DC microstimulation, applied by a point stimulator, is the only modality that can produce therapeutic responses quick enough to eliminate or include therapeutic systems into future treatment protocols. Traditional TENS, applied by pads, is far too inefficient a stimulation to produce beneficial therapeutic response in a short period of time (Cheng & Pomeranz, 1986; Gadsby & Flowerdew, 2000). Therefore, pad stimulation is not the desirable modality for ETPS therapy.

### PART B: ETPS INTEGRATIVE PROTOCOLS

ETPS integrative protocols combine the therapeutic efficacy of acupuncture, intramuscular therapy and neural therapies. As a rule, a mechanical neuropathic assessment is performed and stimulation is applied in stages in order to isolate fascial, neural or meridian systems and to determine and treat the root cause(s) of neuromyofascial pain. The application of these different integrative therapies, methodically and in stages, to isolate different therapeutic systems provides a window of opportunity for health care practitioners (HCP) to diagnose soft tissue pain.

The first step in the treatment of any chronic pain condition is to assess and apply the ETPS Standard Protocol. The ETPS Standard Protocol is designed to address body mechanics, radiculopathy and spine therapy as well as fascial contractions responsible for positive gait and body misalignment. ETPS therapy initially assumes that chronic pain syndromes have a precipitory influence from the hip misalignment and lower back radiculopathy. Therefore, the Standard Protocol will identify or eliminate the nerve root, gait and body mechanics as a major contributor to the chronic pain condition.

Depending on the results of the initial assessment, one or more specific sets of protocols may be performed. The Standard Protocol is described below as well as protocols for back pain, neck pain, fibromyalgia and plantar fasciitis.

#### STANDARD PROTOCOL

1. Assess patient for gait and radiculopathic irregularities.

The first step in standard protocol is to assess the patient in order to determine the degree of discomfort, range of motion or injury, degree of disability and level of pain. Identify gait imbalances through iliac crest levels and leg length discrepancies. Select vertebral segments that display radiculopathic manifestations of trophedema and sudomotor responses.

2. Manually release gait and stretch piriformis.

Manually release the gait using the piriformis stretch (as described in Part A). Start with the side that has the positive (or higher) gait and the shorter leg. Perform stretch bilaterally.

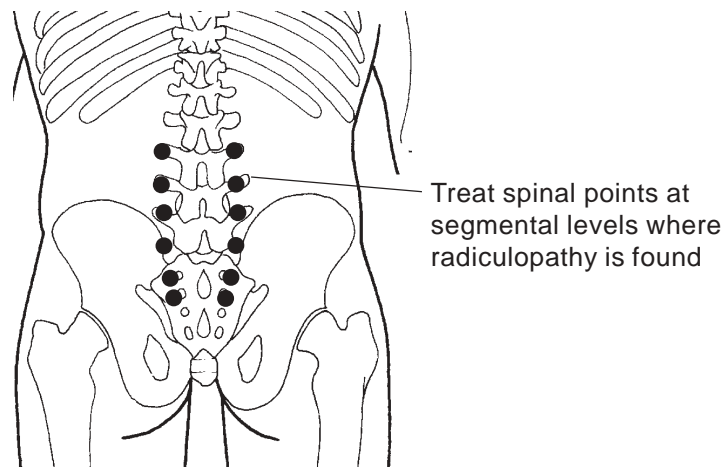
3. Treat radiculopathy at levels identified in Step 1 with a paraspinal release using Back Shu points. These points are located at each segmental level at the spinous process interspace (SPI), approximately 1 in. bilateral at the medial border of erector spinal muscle ridge (two fingers bilateral from midline).

The simultaneous application of two ETPS modalities to these bilateral spinal points provides an exceptional myofascial release of the paraspinal muscles that precipitate radiculopathy and nerve impingement. If ETPS therapy is applied to a series of spinal points correlating to an area of radiculopathy that innervate distal pain or injuries the entire pain condition may be treated. (Figure 54.21)

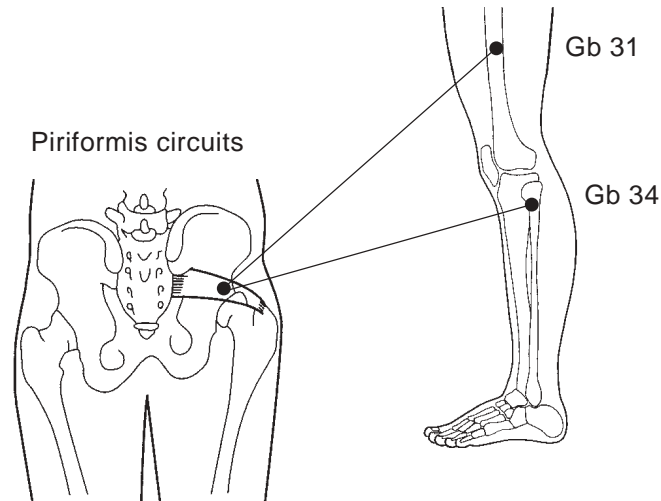
4. Release piriformis with fascial circuit Piriformis – IT band, Piriformis – Gb 34.

Release fascia responsible for gait misalignment by performing a fascial circuit between any tender motor bands palpated throughout the piriformis muscle, the IT band point (Gb 31) and the myofascial point Gb 34 (Figure 54.22). Ask the patient to sit up slowly and then slide off the table placing both feet on the ground at the same time (to prolong treatment outcome).

The Standard Protocol effectively treats lower back radiculopathy and fascial components of gait and overall mechanical imbalances. Many pain conditions throughout the body may be effectively treated with the Standard Protocol, suggesting that radiculopathy and gait imbalances are major contributors to the chronic pain cycle.



**FIGURE 54.21** Illustrates paraspinal points treated in areas of trophedema (nerve root impingement), identified during skin rolling test. (See Figure 54.6)



**FIGURE 54.22** Piriformis circuits are performed to produce myofascial release of hip and leg muscles responsible for gait imbalances. Applied bilaterally after mechanical realignment for optimal, lasting results.

### Other Integrative Protocols

ETPS Integrative protocols go beyond standard procedures with the inclusion of segmental levels, fascial planes and acupuncture-trigger points that work well for individual pain conditions. Additional circuits, fascial groups and modalities are included on a step-by-step basis with an assessment performed at the end of each step or stage.

ETPS protocols are designed to integrate different philosophies and apply treatments in stages to determine the root cause of pain. Once the root causes have been determined, continued treatment may be applied to areas known to produce therapeutic responses. If applied properly, ETPS therapy can diagnosis the root cause of pain with a significant degree of accuracy, thus assisting all HCP in the treatment of chronic soft tissue pain.

In ETPS therapy, the patient is assessed before and after each therapeutic stage to determine the degree of success. With several therapeutic stages in back pain, it is possible to determine which segmental levels, muscle dermatomes and meridians are responsible for the patient's pain in approximately 10 to 15 minutes. Generally, one or more stages will produce pain relief for the majority of patients, thus indicating which dermatomes, segments, muscles and meridians should be investigated further as the source of chronic pain. Stages that produce minimal or negative responses (i.e., the patient and pain are noticeably worse after treatment) should be eliminated in future treatment episodes. Using this therapeutic process of elimination, therapists can investigate and treat patients at the same time, ultimately producing faster and more effective outcomes. After assessing the exact points and therapeutic systems using the ETPS elimination process, concentrate only on those stages that produce positive therapeutic benefits.

Presented below are four additional protocols for the diagnosis and treatment of back pain, neck pain, fibromyalgia and plantar fasciitis.

### BACK PAIN PROTOCOL

#### Step 1 Apply Standard Protocol.

Assess patient after each of the following stages.

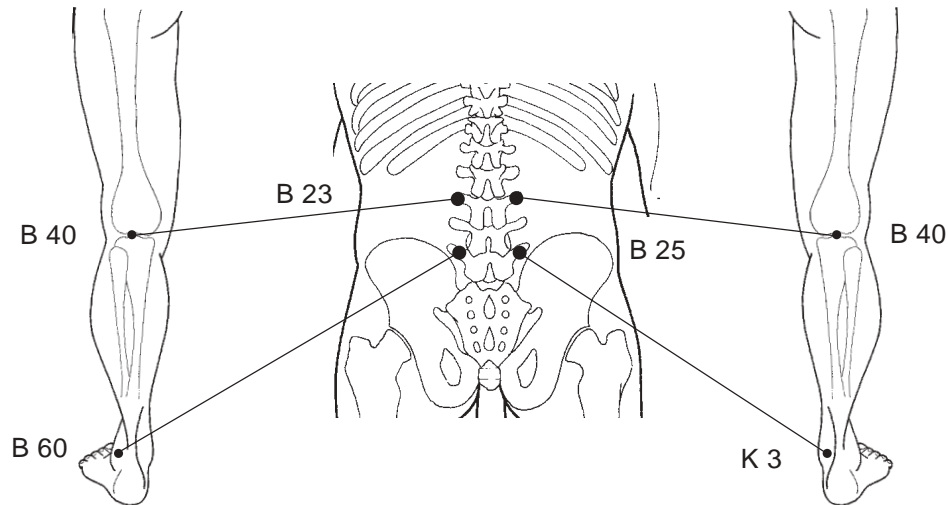
- Check gait–piriformis
- Inspect for signs of neuropathy and radiculopathy, especially between L2–S2.
- Manually release gait
- Perform paraspinal release at segments with trophedema (-ve)
- Circuit piriformis–IT Band (-ve) and piriformis–Gb 34

#### Step 2 Stimulate circuits designed to treat the nerve pathway or meridian involved with injury.

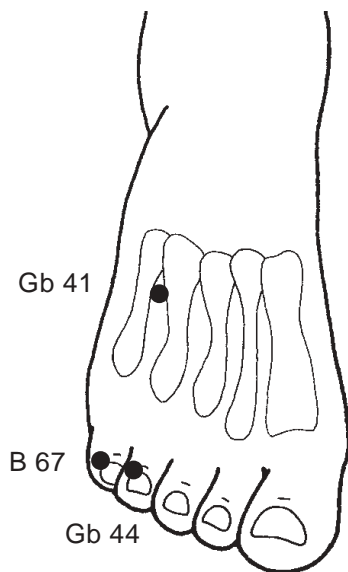
Perform these circuits bilaterally with patient lying in the prone position. Ask patient to sit up and dismount with both feet landing on the floor at the same time. (See Figure 54.23)

- Circuit L2–L3. Interspace with B 40 (low back pain distal point) and treat with negative (vasoconstrictive) polarity.
- Circuit L4–L5. Interspace with B 60 (anatomic and acupuncture trigger point) for patients whose pain becomes more severe throughout the day
- Circuit L4–L5 with K 3 (kidney source point) for patients with back pain and stiffness that is most severe in the morning.

#### Step 3 Stimulate Sacral Triangle and dermatomal points for lateral hip release and spinal pain.



**FIGURE 54.23** Neural circuits performed between paraspinal nerve root points and key distal acupuncture points to reduce upper leg pain and calm nerve pathways resulting from radiculopathy. Circuits B 23–B 40 are treated bilaterally. Circuits B 25–K 3 are integrated bilaterally for back patients with pain aggravation in the morning. Circuits B 25–B 60 are integrated bilaterally for back patients with pain aggravation in the afternoon and evening. Apply vasoconstrictive ETPS Therapy.



**FIGURE 54.24** Distal acupuncture points B 67 and Gb 44 are combined with Gb 41 to produce “sacral triangle”. These points are treated to reduce proximal nerve root pain and for myofascial release of hips in stage three (3) of back pain protocol. Apply vasoconstrictive ETPS Therapy.

If success is limited in the first two steps, Step 3 can often provide immense relief to patients. Stimulation need only be applied for 20 to 30 seconds on the proper dermatome point in order to provide relief. Based on our experience using ETPS therapy, a significant number of patients with back pain will respond only to Step 3. Treat the distal dermatome points involved with painful or radiculopathic vertebral segments and the posterior lateral muscles believed to be involved with mechanical gait imbalances.

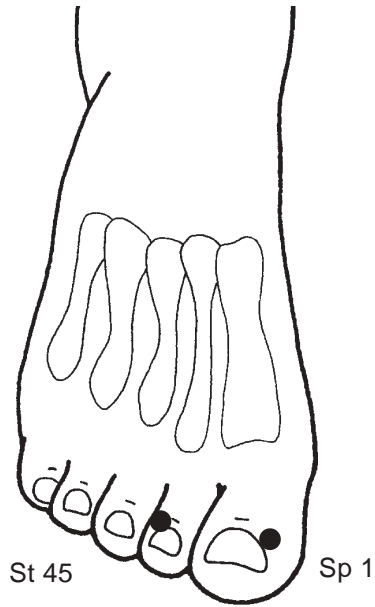
- Sacral triangle includes B 67, Gb 44 and Gb 41. B 67 (located at base of fifth toenail on lateral side) and Gb 44 (located base fourth toenail lateral side) and correlate to S1 and L5 dermatomes and nerve roots. Gb 41 is located at proximal end of the fourth and fifth tendons.

The application of ETPS dermatome points can produce useful information:

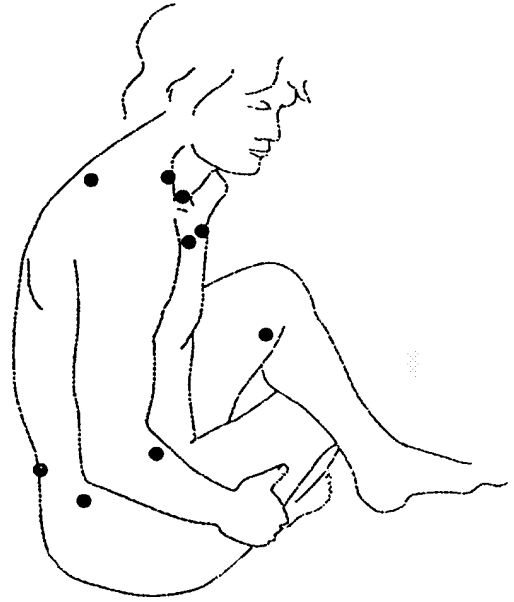
- i. Are stimulated nerve endings most efficacious in the treatment of proximal pain?
- ii. Are the hip and gluteal muscles responsible for back pain? If true, Gb 41 and Gb 44 will be sensitive.
- iii. Is spinal injury or disc bulge responsible for back pain B 67? If true, the spine will be tender.

#### Step 4 Dermatomal points for anterior hip flexors.

Located at the lateral side of the base of the second toenail, St 45 isolates the treatment release of the psoas and hip flexor muscles. (Figure 54.25) With some pain patients, the psoas muscle may be contracted alone or with the piriformis muscle. If pain continues to persist after Steps 1 to 3, a quick stimulation of St 45 (second toe base nail lateral side) will reveal if the psoas muscle is contributing to the pain condition. Patients should be assessed between treatments of both the R and L points to determine which psoas muscle is most involved in the injury. This step was integrated to include both posterior and anterior hip stabilizing muscles in order to determine if they individually or collectively contribute to the patient’s chronic pain state.



**FIGURE 54.25** Illustrates the acupuncture jing well points Sp 1 and St 45 used ipsilaterally for the myofascial release of the psoas and hip flexor muscles. Apply vasoconstrictive ETPS therapy.



**FIGURE 54.26** Tender points are treated at the end of ETPS protocols for additional pain relief. They are identified by the patient and treated in short intense bursts with ETPS stimulation. Apply vasoconstrictive ETPS therapy.

#### Step 5 Neural therapy.

Application of ETPS stimulation to scars that intersect with, or are located in, the dermatomes or on meridians that relate to pain is an effective approach to more complex pain conditions. Inspect for scarring, either surgical or injury related, distal in the dermatomes to the injury and distal proximal to the injury/pain along the meridian. For back pain, inspect for scars along the lateral anterior knees and paraspinal back. If scars exist, stimulate briefly (10 to 15 seconds) at 1/8-inch intervals surrounding the scar. This process has produced effective responses with many patients.

#### Step 6 Tender points.

Tender trigger points are treated as a last step in the therapy because ETPS assumes that all pain is referred from another anatomical area of the body. Therefore, the treatment of local pathology is secondary to root sources of pain (i.e., body mechanics and radiculopathy). However, local pathology can exist and the tender trigger point(s) may be identified by the patient and treated by the therapist after Steps 1 through 5. After identification, apply brief ETPS stimulation of 15 to 20 seconds per point. This technique has proven successful in alleviating the majority of any pain that remains. (See Figure 54.26)

### NECK PAIN PROTOCOL

#### Step 1 Apply Standard Protocol.

Pay special attention to radiculopathy at the L2-L3 interspace levels, as they have a strong influence on neck pain.

Assess patient after each of the following stages.

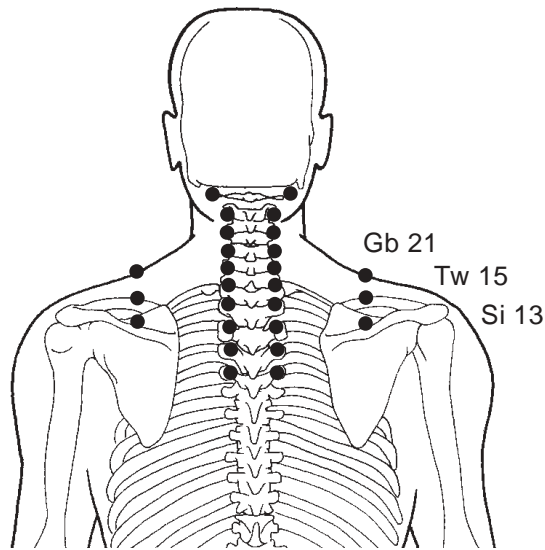
- Check Gait – piriformis
- Look for signs of neuropathy and radiculopathy, especially at the L2-L3 level.
- Manually release gait
- Perform paraspinal release at segments with trophedema (-ve)
- Circuit piriformis - IT Band (-ve) and piriformis - Gb 34

#### Step 2 Posterior Neck and Trapezius release.

- Paraspinally release cervical neck at level of crease identified in Step 1. This step is designed to diagnose and treat the posterior muscles of the neck involved with injury.
- Stimulate Gb 21, Tw 15 and Si 13, designed to release the trapezius, rhomboid and supraspinatus muscles (Figure 54.27).

#### Step 3 Lateral neck release

- Laterally release neck, palpating for motor bands. Stimulate the motor bands at the level of the horizontal neck creases. All contributors to neck and limb disorders, stimulation of these areas is designed to release the scalenes, levator scapula and splenius capitus muscles (Figure 54.28).



**FIGURE 54.27** Illustrates the posterior paraspinal neck points and the trapezius myofascial release points. A positive therapeutic response indicates involvement of these segments and muscles with the injury. Apply vasoconstrictive ETPS Therapy.

**Step 4** Distal point for the neck.

- Si 3: posterior muscles of the neck. Located at the medial end of the distal transverse palm crease. Note: locate and treat this point with the fist clenched. This is the first point to treat when there is a wry neck or torticollis. Treat bi-laterally.

**Step 5** Dermal points for the neck.

Treat these points first if patient's neck is hypersensitive (i.e., post accident/whiplash or post operative). If not hypersensitive, follow protocol order.

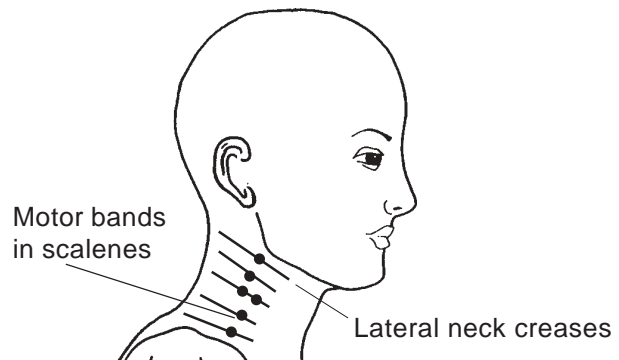
- Li 1: Designed to release SCM ipsilaterally. Located at the radial side of the base of the index fingernail.
- Si 1: Designed to release ipsilateral scalenes. Located at the lateral side of the base of the little fingernail (fifth metacarpal).

**Step 6** Neural therapy.

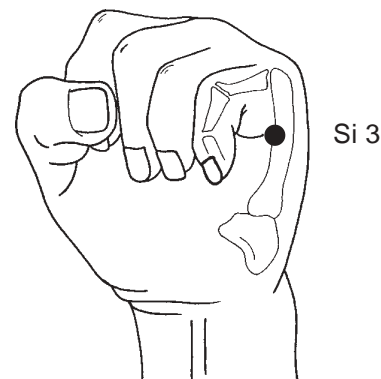
Inspect for scarring, either surgical or injury, distal in the dermatomes from C5-T1 or along any upper limb meridians. For neck pain, inspect for scars around the elbow and wrist.

**Step 7** Tender trigger points.

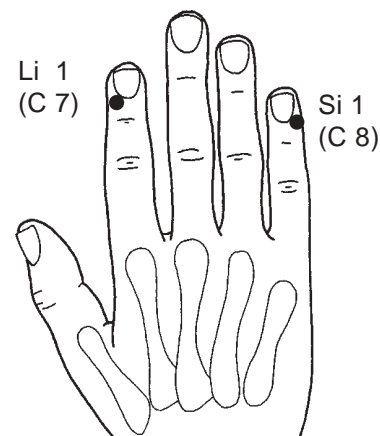
Ask the patient to identify any local tender points remaining in the cervical region. Apply ETPS therapy to these points, usually trigger points (TP's) or acupuncture points (AP's) throughout injured tissue. Brief stimulation of 15 to 20 seconds per point has been successful in alleviating the majority of any pain that remains.



**FIGURE 54.28** Illustrates lateral neck muscles and suggested location of myofascial release points throughout tight motor bands points. Release these with ETPS stimulation for highly effective relief of upper extremity pain. DO NOT apply microcurrent stimulation anterior to the corner of the jaw (over the carotid sinus). Apply vasoconstrictive ETPS Therapy.



**FIGURE 54.29** Confluent acupuncture point Si 3, displays influence over the posterior neck and spine. Often highly sensitive on patients with posterior disc problems. Treat bilaterally, apply vasoconstrictive ETPS Therapy.



**FIGURE 54.30** The hand illustrates the integration of acupuncture jing well points for myofascial release of Sternal Clavicular Mastoid (SCM) using Li 1 and the scalene muscles using Si 1. Treat bilaterally, applying vasoconstrictive ETPS therapy.

## FIBROMYALGIA PROTOCOL

### Step 1 Treat the parasympathetic points (-ve)

Treat the following parasympathetic points. Assess the patient after each stage.

- Lu 9 (Figure 54.31): A powerful vascular and parasympathetic point. Located on the transverse wrist crease, in a hollow on the ulnar side of the radial bone.
- P 6: A good nausea and parasympathetic point. Located three fingers proximal from the most distal wrist crease, deep between the palmaris and flexor carpi tendons.
- H 7: An excellent mind calming and parasympathetic point. Located on the transverse wrist crease, in a hollow on the radial side of the thick flexor carpi ulnaris tendon.
- Sp 6 (Figure 54.32): An immune, parasympathetic and distal pain point for perineum. Located four fingers superior to the medial malleolus and posterior to the tibia bone. Note: press directly against the bone to find this point.
- K 3: A low back pain, congenital energy and parasympathetic point. Located in the hollow midway between the medial malleolus and Achilles tendon. Also used for morning back pain and circuted with B 25 (L4-L5 interspace).
- Cv 17: A respiratory and parasympathetic point. Located on the midline of the sternum, horizontal with the fourth intercostal space.

### Step 2 Apply Standard Protocol.

Assess patient after each stage.

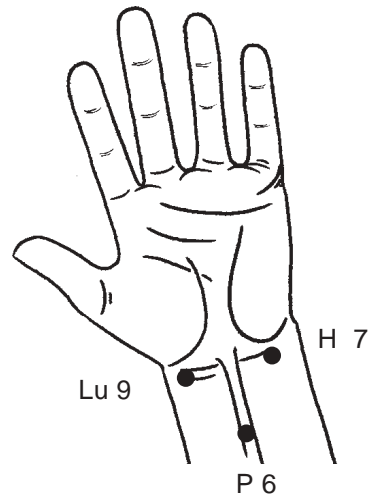
- Check Gait – piriformis
- Look for signs of radiculopathy, (motor bands) especially at T9-10 levels.
- Manually release gait
- Perform paraspinal release from T10–S2 (+ve) encompassing segments with trophedema.  
*Note: Use positive polarity for paraspinal stimulation.*
- Circuit piriformis - IT Band (-ve) and piriformis - Gb 34

### Step 3 Homeostatic point Li 11 (-ve).

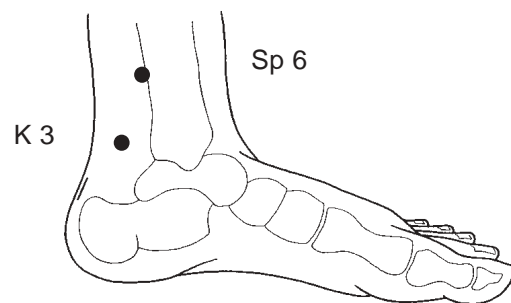
If success is limited in the first two steps, Step 3 can often provide relief to the patient. Stimulation needs only to be applied for 20-30 seconds on the proper dermatome point in order to provide relief. Located at the lateral end of the transverse elbow crease, with the elbow semi-flexed. (Figure 54.35)

### Step 4 Sacral triangle B 67, Gb 44, Gb 41 (-ve) (Figure 54.36)

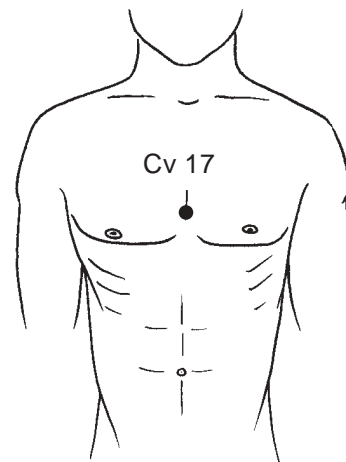
Isolate the treatment release of the psoas muscles.



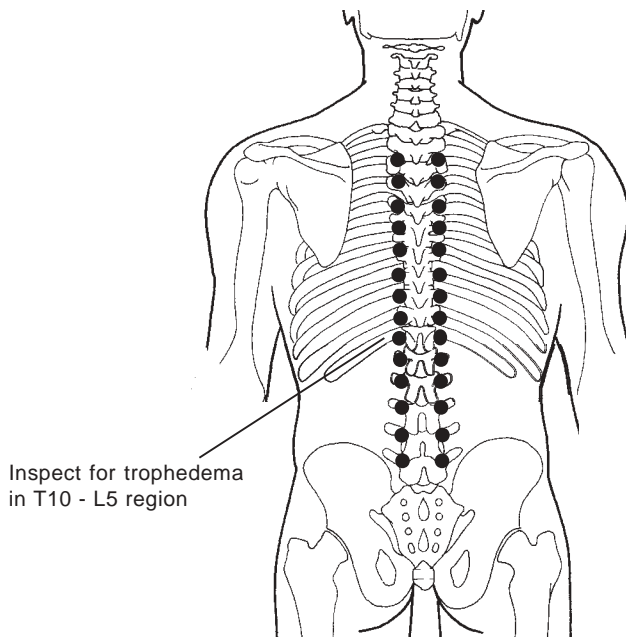
**FIGURE 54.31** Three upper limb parasympathetic points Lu 9, P 6 and H 7, used to deregulate the Autonomic Nervous System (ANS), permitting continued therapy on supersensitive patients. Treat bilaterally, applying vasoconstrictive ETPS Therapy.



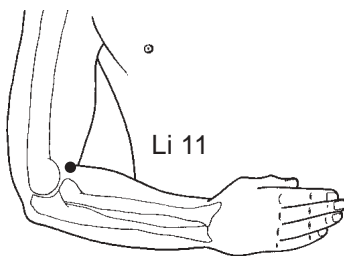
**FIGURE 54.32** Sp 6 and K 3 are lower limb parasympathetic points, used for deregulation of lower viscera, permitting continued therapy on sensitive patients. Treat bilaterally, applying vasoconstrictive ETPS Therapy.



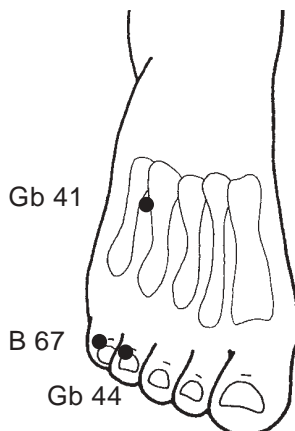
**FIGURE 54.33** Acupuncture point for body calming. Also known as “sea of tranquility”, Cv 17 should ONLY be treated on severe patients, and only AFTER all the above points have been treated.



**FIGURE 54.34** Palpate for paraspinal motor bands throughout the thoracic region. Release identified motor bands with paraspinal points. Apply vasodilative ETPS Therapy.



**FIGURE 54.35** Homeostatic acupuncture point Li 11. Apply vasoconstrictive therapy to right arm and vasodilative therapy to left arm.



**FIGURE 54.36** Sacral triangle may be treated with vasoconstrictive ETPS stimulation for additional relief beyond steps 1 to 3. Note the audible differences between B 67 and Gb 44. A high pitch with Gb 44 denotes hip and fascial pain root, and a high pitch with B 67 denotes spinal radiculopathic involvement in pain cycle.

With some patients, the psoas muscle may be contracted alone or with the piriformis muscle. If pain still exists after Steps 1 through 3, a quick stimulation of St 45 (second toe base nail lateral side) will reveal if psoas muscle is contributing to the pain condition.

Patients should be assessed between treatments of both the R & L points to determine which psoas muscle is most involved in the injury. This step was integrated into this protocol to include both posterior and anterior hip stabilizing muscles in order to determine if they individually or collectively contribute to the patient's chronic pain state.

**Step 5. Release tender trigger points.**

As noted earlier, tender trigger areas are treated as a last step in ETPS therapy because it is assumed that all pain is referred from another anatomical area of the body.

(Figure 54.37)

Ask the patient to identify tender points and apply ETPS therapy to these points (usually TP's or AP's throughout injured tissue). Brief stimulation of 15 to 20 seconds per point has proven successful in alleviating the majority of any pain that remains. After each stage, stop and assess patient. Treat all points bilaterally.

#### PLANTAR FASCIITIS PROTOCOL

**Step 1: Apply Standard Protocol.**

Assess patient after each stage.

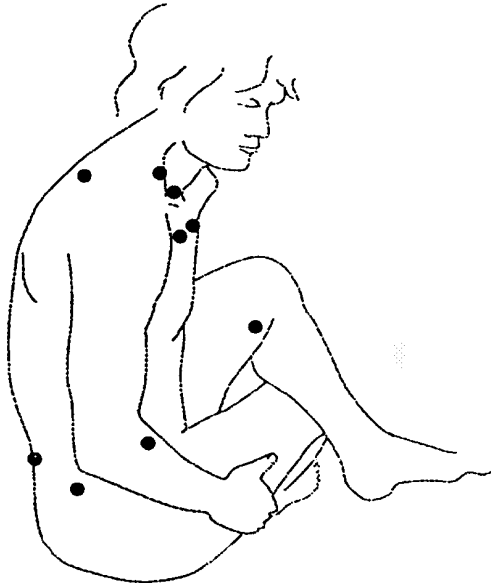
- Check gait – Piriformis
- Look for signs of neuropathy and radiculopathy.
- Manually release gait.
- Perform paraspinal release from L4–S2 (encompassing segments with trophedema) (Figure 54.38)
- Circuit piriformis - IT Band and Piriformis - Gb 34

**Step 2 Myofascial release of fascial overlay throughout calf muscles.**

- B 57 (Figure 54.39): Located at the Achilles tendonis muscular junction, this is an excellent point for releasing the entire calf area.

**Step 3 Treat local points for pain relief.**

- K 3 (Figure 54.40): The best point to treat for patients who display a stiff back in the morning. Located in the hollow between the medial malleolus and the Achilles tendon.



**FIGURE 54.37** Two to Three tender points may be identified by patient and treated AFTER the previous steps are completed. NOTE: do not apply stimulation to more than three tender points, as aggravation of symptoms is common with excessive stimulation.

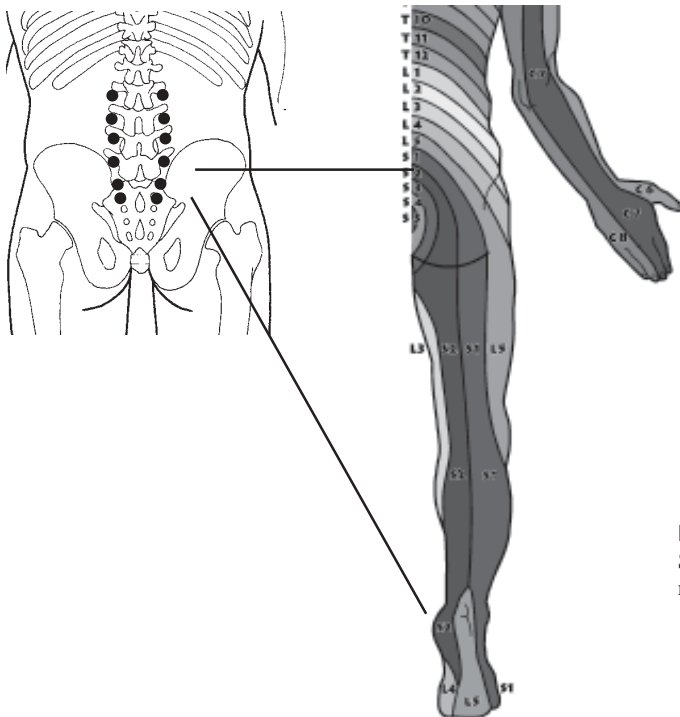
- K 5: Located one thumbs width below K 3.
- K 6: Located in the hollow just below the medial malleolus.
- B 60 (Figure 54.41): Located in the hollow between the lateral malleolus and the Achilles tendon. Very tender on sciatica patients.
- B 62: Located in the hollow just below the lateral malleolus.

Step 4. Treat dermatome points.

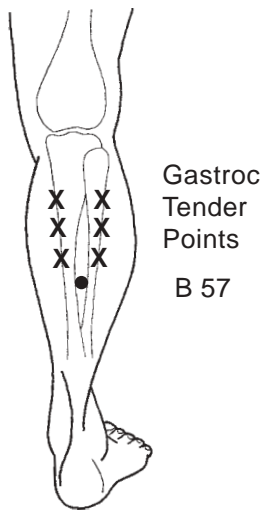
- B 67 (Figure 54.42): At the base of the baby toenail, on the lateral side. Innervation - S1
- Gb 44: At the base of the fourth toe nail, on the lateral side. Innervation - L5
- St 45: At the base of the 2nd toenail, on the lateral side. Innervation - L5
- Sp 1: At the base of the big toe nail, on the medial side. Innervation - L4

Step 5. Tender trigger points.

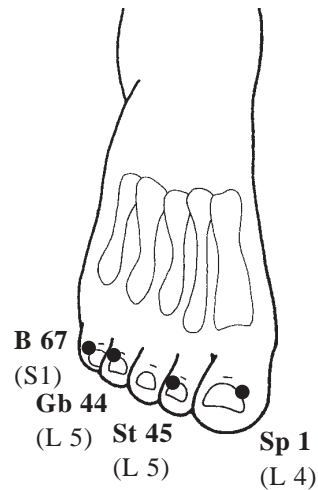
Ask the patient to identify tender points and apply ETPS therapy to these points, (usually TP's or AP's throughout injured tissue). Apply brief stimulation of 15 to 20 seconds per point. (Figure 54.43)



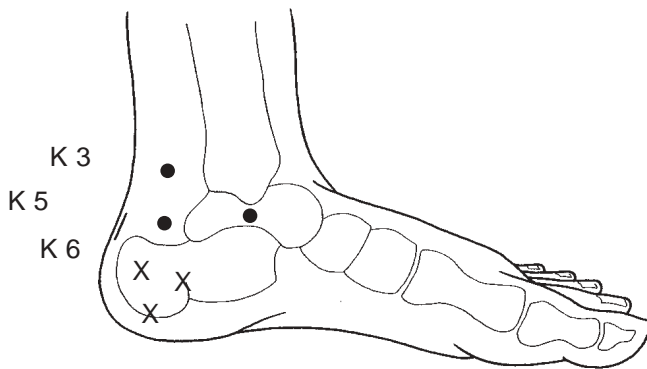
**FIGURE 54.38** Inspect for trophedema at segmental levels L 4–S 2, as identified with skin rolling test. (see figure 6). Paraspinally release with vasoconstrictive ETPS therapy.



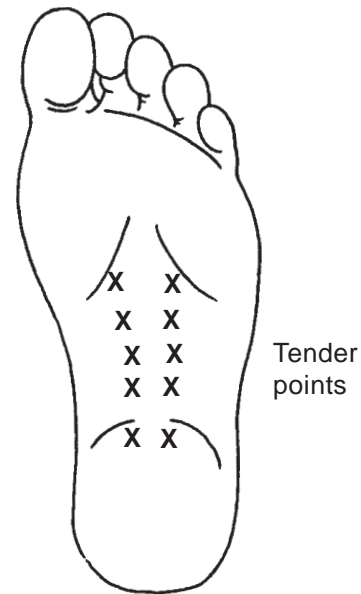
**FIGURE 54.39** Release acupuncture point B 57 and tender points located throughout motor bands (identified through palpation) using vasoconstrictive ETPS therapy.



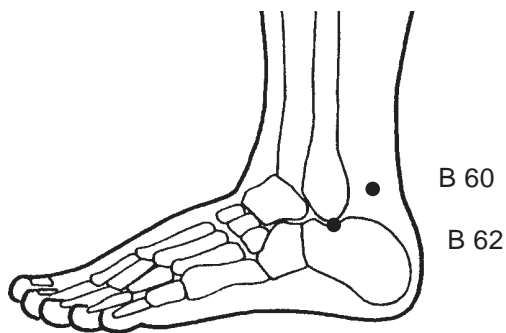
**FIGURE 54.42** Distal “Jing Well” acupuncture points Sp 1, St 45, Gb 44, and B 67. Treat for additional relief of Plantar fasciitis pain using vasoconstrictive ETPS Therapy. NOTE audible differences between points and correlate to dermatomes for clues to root causes of pain.



**FIGURE 54.40** Local medial acupuncture points K 3, K 5, and K 6 which are treated for additional relief from plantar fasciitis pain. Treat with vasoconstrictive ETPS Therapy.



**FIGURE 54.43** Apply vasoconstrictive ETPS therapy to tender points identified by patient on plantar region of foot.



**FIGURE 54.41** Local lateral acupuncture points B 60, B 62 which are treated for additional relief from plantar fasciitis pain. Treat with vasoconstrictive ETPS Therapy.

## CLINICAL RESEARCH STUDY

In a pilot study on Carpal Tunnel Syndrome recently completed at the Canadian Centre for Integrative Medicine, Markham, Ontario. Dr. Gordon Ko (Physiatrist, American Association of Electrodiagnostic Medicine) recorded improvements in five consecutive patients who completed ETPS (one time per week for 4 – 6 weeks). Using the Neuromax 1004 (including skin temperature measurements), the pre- and post- treatment median nerve latencies and amplitudes improved (9 hands). The means scores are listed below with range in brackets.

Mean Values	Pre-Treatment	Post-Treatment
Distal Motor Latency	4.61 msec (3.8 to 6.0)	4.22 msec (3.7 to 5.9)
Sensory Onset Latency		
Palmar	1.98 msec (1.5 to 3.0)	1.81 msec (1.5 to 2.9)
2nd & 3rd Digits	3.13 msec (2.5 to 4.2)	2.93 msec (2.5 to 3.6)
Sensory Amplitudes		
Palmar	37.0 uV (19.3 to 99.0)	44.5 uV (29.3 to 120.3)
2nd & 3rd Digits	13.6 uV (5.0 to 22.7)	16.7 uV (5.3 to 26.0)

Clinical improvement was reported in all patients without any significant adverse effects.

One patient with severe CTS who completed the “Dash” (Disabilities of the arm, shoulder, hand) survey demonstrated marked improvement with a pre-score of 20/100 and a post-score of 1.7/ 100 (a higher score indicates increased functional limitations). Prior to treatment, the patient’s right hand sensory responses were absent. After treatment, palmar and 3<sup>rd</sup> digit responses were measurable.

Further research is required to verify the efficacy of treatment and supporting data. A call for patients is now underway to proceed with a larger controlled study with Dr. Gordon Ko at the University of Toronto.

## ETPS NEUROPATHIC THERAPY CASE STUDY

A case study of the benefits of ETPS Neuropathic Therapy on 345 chronic pain patients was performed. Patients were all over the age of 65, and divided into two groups: one group treated daily for three weeks, one

group treated themselves weekly for three months. Assessments were performed at the beginning and end of each time frame.

Mean scores improved in both groups without any adverse side effects. A significant improvement was reported in the mean score with patients listed below:

Mean Values	Pre-Treatment	Post-Treatment
Average pain score: Daily n = 293	7.48/10 (9.9 to 5.8)	2.99/10 (6.3 to 1.5)
Average pain score: Weekly n = 52	6.13/10 (8.5 to 4.2)	2.35/10 (6.8 to 0.5)

Clinical improvement was reported in all patients without any adverse side effects. Further research is required to verify the efficacy of treatment and accuracy supporting data.

## CONCLUSION

ETPS therapy incorporates acupuncture, osteopathic, trigger point, neuromuscular & neural therapies into simple, easy to use protocols. With this approach, it is possible to integrate different philosophies and access a wide variety of soft tissue pains using one modality. With back pain, an exceptionally common condition, each stage in an ETPS protocol treats a specific pathway, group of muscles, segmental levels, acupuncture meridian or scar. Through this step-by-step elimination process, it is possible to identify and treat those levels, muscles or meridians at the root of a patient’s pain.

Although ETPS therapy has been able to make modest breakthroughs in the diagnosis and treatment of chronic pain through its synthesis of different modalities, additional research is required to advance the body of knowledge. Perhaps an even greater challenge than pure research is the need for competing disciplines to work cooperatively by reducing the barriers that compartmentalize medicine. Drawing from the Oriental paradigm, the advancement of knowledge and the pursuit of truth begin with questions, rather than proclamations of answers. This paradigm is the foundation of ETPS therapy, “How can the constituent elements of medicine be combined to advance the treatment of chronic pain?”

## ACKNOWLEDGMENT

The author wishes to thank Chris Stillinger for the artwork in this chapter.

## REFERENCES

- Andersson S.A. (1979) Pain control by sensory stimulation. In J.J. Bonica (Ed.), *Advances in pain research and therapy* (Vol. 3) (pp. 561-585) New York: Raven Press
- Augustinsson, L.E., et al. (1977) Pain relief during delivery by transcutaneous electrical nerve stimulation. *Pain*, 4, 59-65.
- Becker, R.O. & Selden, G. (1987). *The body electric, electro-magnetism and the foundation of life*. New York: Quill Press.
- Bradley, W.G. (1974). *Disorders of peripheral nerves*. Oxford: Blackwell Scientific Publications.
- Bronzino, J.D. (1998). *The biomedical engineering handbook*. Boca Raton: CRC Press.
- Cannon, W.B., & Rosenbluth, A. (1949). *The supersensitivity of denervated structures*. New York: Macmillan.
- Cheng, R., & Pomeranz, B. (1986). Electrotherapy of chronic musculoskeletal pain: comparison of electroacupuncture acupuncture-like TENS. *Clinical Journal of Pain*, 2, 142.
- Cheng, R., McKibbin, L., Roy, B., & Pomeranz, B. (1980). Electroacupuncture elevates blood cortisol levels in naive horses; sham treatment has no effect. *International Journal of Neuroscience*, 10(2-3), 95-97.
- Christopher, D., Lorenzo, B., Zirbs, A., Chantraine, A., & Visser, T.L. (1992). Electroacupuncture in fibromyalgia: Results of a controlled trial. *British Medical Journal*, 305, 1249-1252.
- Fambrough, D.M., Hartzell, H.C., Powell, J.A., Rash, J.E., & Joseph, N. (1974). *Differentiation and organization of a post-synaptic cell – the skeletal muscle fiber; synaptic transmission and neuronal interaction*. New York: Raven Press.
- Fisher, H.W. (1992). Acute low back pain treated by spinal manipulation and electronic acupuncture. *Journal of Manipulative and Physiological Therapeutics* 15(3), 199-202.
- Friberg, O. (1983). Clinical symptoms and biomechanics of lumbar spine and hip joint in leg length inequality. *Spine* 8(6),643-651.
- Gadsby, J.G., & Flowerdew, M.W. (2000) The effectiveness of transcutaneous electrical nerve stimulation (TENS) and acupuncture-like transcutaneous electrical nerve stimulation (ALTENS) in the treatment of patients with chronic low back pain. *Cochrane Database System Review*, 2, CD2000210.
- Gunn, C.C. (1980). "Prespondylosis" and some pain syndromes following denervation. *Supersensitivity* 5(2), 185-192.
- Gunn, C.C., et al. (1976). Tenderness at motor points: A diagnostic and prognostic aid for low-back injury. *Journal of Bone and Joint Surgery*, 58A(6), 815-825.
- Gunn, C.C., et al. (1978). Early and subtle signs in low-back sprain. *Spine* 3(3), 267-281.
- Gunn, C.C., & Milbrandt, W.E. (1976). Acupuncture loci: A proposal for their classification according to their relationship to known neural structures. *American Journal of Chinese Medicine*, 4(2),183-195.
- Gunn, C.C., & Milbrandt, W.W. (1997). Utilizing trigger points. *Osteopathic Physiology*, 44(3), 29-52.
- Hartley, A. (1989). *A pain control manual: Point locations for musculoskeletal injuries and transelectrical nerve stimulation techniques*. Toronto: Anne Hartley.
- Lehmann, T.R., Russell, D. W., Spratt, K.F., Liu, YK., Fairchild, M.L., & Christensen, S. (1986). Efficacy of electro acupuncture and TENS in the rehabilitation of chronic low back pain patients. *Pain*, 26(3), 277-290.
- Loh, L., & Nathan, P. W. (1978). Painful peripheral states and sympathetic blocks. *Journal of Neurology, Neurosurgery, and Psychiatry*, 41, 664-671.
- Low, J., & Reed, A. (1994). *Electrotherapy explained: Principles and practice* (2nd ed.). Wobum, MA: Butterworth Heinemann.
- Martelete, M., & Fiori, A.M. (1985). Comparative study of the analgesic effect of transcutaneous nerve stimulation (TNS), electroacupuncture (EA), and meperidine in the treatment of post operative pain. *Acupuncture Electrotherapeutics Research*, 10, 183-193.
- Pomeranz, B. (1981). Neural mechanisms of acupuncture analgesia. In Lipton, S. (Ed.), *Persistent pain* (Vol. 3, pp. 241-257). New York: Academic Press.
- Pomeranz, B., & Niziak, G. (1987). Codetron, a new electrotherapy device Overcomes the habituation problems of conventional TENS devices. *American Journal of Electromedicine*, first quarter, 22-26.
- Pomeranz, B., et al. (1988). Electroacupuncture suppression of a nociceptive reflex is potentiated by two repeated electroacupuncture treatments: The first opioid effect postulates a second nonopioid effect. *Brain Research*, 452(1-2), 232-236.
- Robinson, A.J., & Mackler, L.S. (1995). *Clinical electrophysiology: Electrotherapy and electro physiologic testing*. Baltimore: Lippincott, Williams & Wilkins.
- Shriber, W.J. (1981). *A Manual of Electrotherapy* (4th ed.).
- Sola, A.E. (1981). Myofascial trigger point therapy. *Resident and Staff Physician*, 27(8), 38-46.
- Sola, A.E. (1984). Treatment of myofascial pain syndromes. In C. Benedetti, C.R. Chapman, & G. Morrica (Eds.), *Advances in pain research and therapy*, Vol. 7. New York: Raven Press.
- Statistics Canada, Canadian social trends, absenteeism at work. *Perspectives*, Spring 1992.
- Thomas, P.K., & Ochoa, J. (1993). Symptomatology and differential diagnosis of peripheral neuropathy: clinical features and differential diagnosis. In P.J. Dyck & P.K. Thomas (Eds.), *Peripheral neuropathy* (pp. 749-774). Philadelphia: Saunders.
- Travell, J.G., & Simons, D.G. (1998). Myofascial pain and dysfunction: The trigger point manual (Vol. 1 & 2). Baltimore; Lippincott, Williams & Wilkins.
- Yochum T., & Barry, M. (1994). Examination and treatment of the short leg. *Year-end Clinical Compendium. American Chiropractic Association Journal of Chiropractic*.